

## The case history of a toxic sting of a *Leiurus abdullahbayrami* scorpion in Turkey

Michael Seiter, Halil Koç, Alexander Ullrich & Ersen Aydın Yağmur



doi: 10.5431/aramit5109

**Abstract.** Scorpion stings are very common in Turkey. Nevertheless, they are not well documented in the literature and were never reported for the recently described scorpion species *Leiurus abdullahbayrami* Yağmur, Koç & Kunt, 2009. Here, we report a case in which a 30-year-old male was stung by a *L. abdullahbayrami* scorpion in the field. He was directly brought to the emergency department of the local hospital. The symptomatic process was observed and documented. In this case, no antivenom was necessary; we hypothesize that the scorpion has used most of its venom in a previous incident (explained in further detail below) and was therefore not able to inject a normal dosage.

**Keywords:** Scorpion sting, south-eastern Anatolia, symptomatic process

**Zusammenfassung.** Der klinische Verlauf eines giftigen Stiches des Skorpions *Leiurus abdullahbayrami* in der Türkei. Skorpionstiche kommen in der Türkei häufig vor. Dennoch sind sie nur wenig in der Literatur dokumentiert und es war noch kein Stich des erst vor wenigen Jahren beschriebenen Skorpions *Leiurus abdullahbayrami* Yağmur, Koç & Kunt, 2009 bekannt. Wir berichten über den Stich eines 30-jährigen Mannes in der freien Natur und über seine medizinische Behandlung. Er wurde direkt in ein nahe gelegenes Krankenhaus gebracht. Der symptomatische Verlauf wurde beobachtet und dokumentiert; von der Verabreichung eines Gegengiftes wurde abgesehen. Wir vermuten, dass der Skorpion kurz vorher eine große Giftmenge abgegeben hat (wird im Detail erläutert) und daher nicht in der Lage war eine normale Giftmenge zu injizieren.

Scorpions (Scorpiones) belong to the class Arachnida and have a near worldwide distribution. They can be easily distinguished from other arthropods by their morphological structures (Polis 1990). All scorpion species bear a venom gland and are able to sting, but only a handful of them are potentially lethal to humans. As their venom can have lifelong consequences for humans (i.e. respiratory and/or cardiovascular diseases) they are considered as medically important arthropods (e.g. Dittrich et al. 1995, Hisham 1997). Species of medical importance are all found within two families, Buthidae and Hemiscorpiidae, but are spread over several genera: *Androctonus*, *Buthus*, *Centruroides*, *Leiurus*, *Mesobuthus*, *Parabuthus*, *Tityus* and *Hemiscorpius*. Their distribution covers Central and South America (incl. Mexico), the Middle East, northern Africa and southern Africa (e.g. Adıgüzel 2010, Adolfo et al. 2003, Borges et al. 2012, Pardal et al. 2014, Pipelzadeha et al. 2007, Reckziegel & Pinto 2014).

Scorpion stings are a common occurrence in Turkey. The majority of them are known from the Antalya, Kahramanmaraş, Mersin and Hatay Provinces in the Mediterranean region. However, deaths have been rarely documented and, when occurring, were due to cardiovascular and respiratory failure within the first 24 hours of hospitalization (Ozkan et al. 2007). In south-eastern Anatolia, seven scorpion species from the family Buthidae are known: *Androctonus crassicauda*, *Buthus macrocentrus*, *Compsobuthus matthiesseni*, *Hottentotta saulcyi*, *Leiurus abdullahbayrami* (*L. abdullahbayrami* was previously identified as *L. quinquestriatus* in Turkey and was classified as a new species by Yağmur et al. 2009), *Mesobuthus phillipsii* and *Mesobuthus nigrocinctus*. Of these

seven, three have been considered dangerous to humans: *A. crassicauda*, *L. abdullahbayrami* and *H. saulcyi* (Ozkan & Kat 2005, Ozkan et al. 2006, 2011).

The species in our case report is *L. abdullahbayrami*, which is only distributed in Turkey and Syria (Yağmur et al. 2009, Khalil & Yağmur 2010). In a recent study, Ozkan et al. (2011) documented the lethality and biological effects of *L. abdullahbayrami* scorpion venom in mice. They reported the median lethal dose of the venom to be 0.19 mg/kg (LD<sub>50</sub>) by subcutaneous injection in mice (Ozkan et al. 2011). By comparison, the median lethal dose of *L. quinquestriatus* – previously considered the most lethal species for mice – is 0.25 mg/kg (Watt & Simard 1984).

Here we present a detailed progression of symptoms in a 30 year-old man from Central Europe after envenomation by an adult *L. abdullahbayrami* female. This report is the first documented envenomation from the most toxic scorpion species known to science.

### Case report

A 30-year-old male was stung by a scorpion in south-eastern Anatolia (c/o Küplüce in Kilis Province, close to the Syrian border) on 06. September 2014 at 9:30 p.m. in the tip of the right thumb. Afterwards, the scorpion was caught and was brought to the laboratory for identification, where it was confirmed to be an adult *L. abdullahbayrami* female, which is now deposited in the collection of the Natural History Museum Vienna (Fig. 1). The event took place at night, approximately 12 kilometres away from the nearest hospital. The habitat was typical for this scorpion species (Fig. 2) and has been documented before (Yağmur et al. 2009). Within 20 minutes, the person was brought to the emergency department in Kilis.

Upon arrival, the patient complained of severe local pain spreading from his right thumb (Fig. 3). He was very calm and showed no sign of abnormal blood pressure and pulse. The patient was a smoker and there is no history of hypertension or cardiac diseases in the recent family tree. It is worth mentioning that this scorpion specimen was previously inadvertently damaged by turning a stone.

Michael SEITER, Group of Arthropod Ecology and Behavior, Division of Plant Protection, Department of Crop Sciences, University of Natural Resources and Life Sciences, Vienna, Austria; E-mail: michael.seiter@boku.ac.at

Halil KOÇ, Sinop University, Science and Art Faculty, Biology Department, Sinop, Turkey; E-mail: halilkoc@sinop.edu.tr

Alexander ULLRICH, Gartenstraße 22, 59514 Welver, Germany. E-mail: alex@hottentotta.com

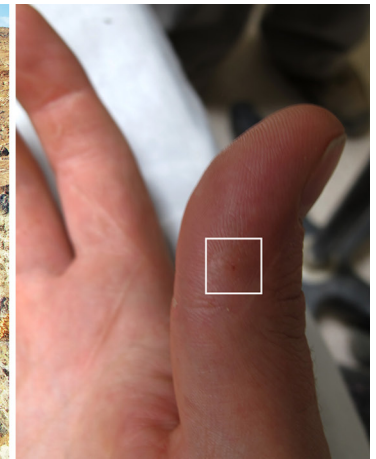
Ersen Aydın YAĞMUR, Alaçehir Vocational School, Celal Bayar University, Manisa, Turkey; E-mail: ersen.yagmur@gmail.com



**Fig. 1:** *Leiurus abdullahbayrami*, adult female from Kilis Province in Turkey



**Fig. 2:** Envenomation locality in Kilis Province close to the Syrian border



**Fig. 3:** Sting site at the time the patient was monitored in hospital after one hour of envenomation. White rectangle shows the area where the aculeus penetrated the skin.

Below are the observations made by the patient himself and two eyewitnesses. After arrival of the ambulance at 9:55 p.m., the medical team decided to monitor the patient and not immediately administer antivenom. However, one litre of sodium chloride was intravenously applied as an infusion and antihistamine was administered. Additionally, in order to reduce the pain, an initial mild painkiller was dispensed in the envenomation area. A full blood count, liver function, electrolyte blood levels and other routine laboratory tests were conducted and all showed normal values after 25 minutes of envenomation.

After approximately one hour, the acute pain (see Tab. 1 for the progress) radiated from the fingertip to the wrist. The area where the aculeus penetrated the skin started to redden. Up to this point, severe pain would sporadically set in and last for approximately four minutes at a time. The patient tried to stay as calm as possible and hold his thumb straight using his muscular strength to avoid additional pain caused by bending the finger or moving it quickly around. Additionally, every few minutes, seizures went down to the feet. After one hour,

**Tab. 1:** Severity and progression of envenomation caused by an adult *Leiurus abdullahbayrami* female scorpion sting. Time frame is stated in minutes after envenomation; pain scale from 1 to 10 indicates the subjective pain level described by the patient: 1 is mild pain and 10 is hardly bearable. Medical treatment documents the proceedings of the medical team over time

Time-frame	Area of pain	Pain level	Medical treatment
0	Fingertip	1	None
2-10	Fingertip, spreading out	2	None
25	Complete finger	3	Sodium chloride, antihistamine and mild painkiller
60	To the wrist	5	None
120	To the crook of the arm	8	None
180	To the shoulder	10	Narcotic painkiller
240	To the shoulder	9	None
300	Complete arm, decreasing	8	None
360	Complete arm	6	None
720	Arm-bed	5	Ibuprofen Atid 1600 mg

considering the more or less good condition of the patient, the medical team maintained their decision not to inject antivenom. Nevertheless, the pain was incredibly powerful. The patient held the railings of the bed tightly and his body was shaking because of the relapsing seizures. After two hours, the critical climax had been reached. The patient described this moment as the most painful minutes in his life. The skin of his arm began to contract and the first growth of pimples and small blisters became visible. Any contact of the skin initiated nearly unbearable pain and any active muscle movement in the thumb itself and the hand was impossible. After three hours, the medical team decided to administer new painkillers. They decided to evaluate the patient's condition every ten minutes to decide if antivenom would be used or not. After reaching this peak, the pain declined. At the end of the six hour observation and treatment period the patient was discharged with no further therapy or medication. The pain was still present, and vertical movement of the arm was not possible. During the following night, the patient was not able to sleep, any slow movement of the arm caused pain. In the morning of the next day (around 14 hours after the sting), a pharmacy was visited and some Ibuprofen Atid 800 mg was bought. After two tablets, the pain reached a bearable level, however numbness in the thumb remained and moving the arm caused pain. The stung area remained hypersensitive and touching the thumb resulted in paresthesia, which gradually resolved over two days. After ten days, another blood test was conducted and it showed more or less normal values.

## Discussion

The genus *Leiurus* is one of the most dangerous in the world and is responsible for many scorpion envenomation cases in different countries in North Africa, the Middle East and the Arabian Peninsula. Therefore, the species *L. abdullahbayrami* is considered to be the most significant to humans in Turkey (Dittrich et al. 1995, Ozkan et al. 2011). This species is reported from Adıyaman, Gaziantep, Hatay, Kilis, Mardin and Şanlıurfa Provinces in south-eastern Turkey and also from northern Syria (Yağmur et al. 2009, Khalil & Yağmur 2010). In these regions, scorpionism is de facto a known medical problem and many scorpion stings have been reported in re-



cent history (for a review see Ozkan et al. 2007). Generally, the only specific treatment against scorpion poisoning is species-specific antivenom. It is often used, but its effectiveness is unclear and often disputed (Ozkan et al. 2011).

In Turkey the Refik Saydam Public Health Agency is the producer of the antivenom, compounded from the species *Androctonus crassicauda*. This antivenom has been used for all scorpion stings in Turkey (Adıguzel et al. 2007). Cesaretli & Ozkan (2010) presented a review of epidemiological and clinical aspects of scorpion stings in Turkey and revealed that most patients (more than 50%) were only treated symptomatically and only around one third of all cases were treated with antivenom. Therefore, the treatment at the Kilis hospital was a normal and proven protocol.

In conclusion, the initial sting caused mild pain and progressed to a hardly bearable one within three hours. The pain originated in the thumb of the right hand and progressed to the shoulder of the patient. Almost all systemic scorpion envenomation produce pain at the site of the sting and several other symptoms can follow. After the alpha and other toxins, the excess can cause adrenergic, cholinergic effects, sympathetic and parasympathetic effects respectively, and neuromuscular excitation (Isbister & Bawaskar 2014). In this case, only sympathetic effects occurred and only some of the classic effects were seen, i.e. irritability, agitation and seizures. The patient suffered pain, but no cardiovascular effects, arrhythmias, hypotension, multi-organ failure or respiratory failure (Yağmur et al. 2015).

Since the sting was by the most venomous species known to science, the patient was very lucky that a stone, and not his thumb, was the first encounter with the culprit. Some plausible explanations might be that (i) the specimen previously lost some of its venom during the first encounter with a stone, (ii) the scorpion had recently used its venom stinging some other animals and was therefore exhausted, (iii) the species' venom is more toxic to mice than humans, or (iii) some combination of these. Another possible explanation for this is that the toxic sting contained only a so-called pre venom, highly painful and toxic but with a different mixture of ingredients than a normal sting (Inceoglu et al. 2003). This study did not scrutinize to what extent the venom of *L. abdullabbayrami* is deadly or not and, therefore, does not portray the real potential power of the venom. However, it constitutes an important starting point and stimulus for exciting future reports. Further research should quantify the true effects and the whole clinical spectrum of the scorpion sting.

### Acknowledgements

We want to thank Martin Gamache (Canada) for the careful review of a previous version of the manuscript. Furthermore we want to thank Gökhan Aksel (Department of Emergency Medicine, Istanbul) for literature.

### References

Adıguzel S 2010 In vivo and in vitro effects of scorpion venoms in Turkey: a mini-review. – *Journal of Venomous Animals and Toxins including Tropical Diseases* 16: 198–211 – doi: [10.1590/S1678-91992010000200004](https://doi.org/10.1590/S1678-91992010000200004)

Adıguzel S, Ozkan O & Inceoglu B 2007 Epidemiological and clinical characteristics of scorpionism in children in Sanliurfa, Turkey. – *Toxicon* 49: 875–880 – doi: [10.1016/j.toxicon.2006.12.012](https://doi.org/10.1016/j.toxicon.2006.12.012)

Adolfo R, De Roodt AR, García SI, Salomón OD, Segre L, Dolab JA, Funes RF & Titto EH 2003 Epidemiological and clinical aspects

of scorpionism by *Tityus trivittatus* in Argentina. – *Toxicon* 41: 971–977 – doi: [10.1016/S0041-0101\(03\)00066-7](https://doi.org/10.1016/S0041-0101(03)00066-7)

Borges A, Miranda RJ & Pascale JM 2012 Scorpionism in Central America, with special reference to the case of Panama. – *Journal of Venomous Animals and Toxins including Tropical Diseases* 18: 130–143 – doi: [10.1590/S1678-91992012000200002](https://doi.org/10.1590/S1678-91992012000200002)

Cesaretli Y & Ozkan O 2010 Scorpion stings in Turkey: epidemiological and clinical aspects between the years 1995 and 2004. – *Revista do Instituto de Medicina Tropical de São Paulo* 52: 215–220 – doi: [10.1590/S0036-46652010000400010](https://doi.org/10.1590/S0036-46652010000400010)

Dittrich K, Power AP & Smith NA 1995 Scorpion sting syndrome – a ten-year experience. – *Annals of Saudi Medicine* 15: 148–155

Hisham MA 1997 Scorpion sting syndrome: epidemiology, clinical presentation and management of 2240 cases. – *La Revue de Santé de la Méditerranée orientale* 3: 82–99

Inceoglu B, Lango J, Jing J, Chen L, Doymaz I, Pessah IN & Hammock D 2003 One scorpion, two venoms: Pre venom of *Parabuthus transvaalicus* acts as an alternative type of venom with distinct mechanism of action. – *Proceedings of the National Academy of Sciences of the United States of America* 100: 922–927 – doi: [10.1073/pnas.242735499](https://doi.org/10.1073/pnas.242735499)

Isbister GK & Bawaskar HS 2014 Scorpion envenomation. – *The New England Journal of Medicine* 371: 457–463 – doi: [10.1056/NEJMr1401108](https://doi.org/10.1056/NEJMr1401108)

Khalil N & Yağmur EA 2010 *Leiurus abdullabbayrami* (Scorpiones: Buthidae), a new species for the scorpion fauna of Syria. – *Serket* 12: 1–6

Ozkan O & Kat I 2005 *Mesobuthus eupeus* scorpionism in Sanliurfa region of Turkey. – *Journal of Venomous Animals and Toxins including Tropical Diseases* 11: 479–491 – doi: [10.1590/S1678-91992005000400008](https://doi.org/10.1590/S1678-91992005000400008)

Ozkan O, Adıguzel S, Yakistiran S, Cesaretli Y, Orman M & Karaer KZ 2006 *Androctonus crassicauda* (Olivier 1807) scorpionism in the Sanliurfa Provinces of Turkey. – *Türkiye Parazitoloji Dergisi* 30: 239–245

Ozkan O, Uzun R, Adıguzel S, Cesaretli Y & Ertek M 2007 Evaluation of scorpion sting incidence in Turkey. – *Journal of Venomous Animals and Toxins including Tropical Diseases* 14: 128–140 – doi: [10.1590/S1678-91992008000100010](https://doi.org/10.1590/S1678-91992008000100010)

Ozkan O, Yağmur EA & Ark M 2011 A newly described scorpion species, *Leiurus abdullabbayrami* (Scorpion: Buthidae), and the lethal potency and in vivo effects of its venom. – *Journal of Venomous Animals and Toxins including Tropical Diseases* 17: 414–421 – doi: [10.1590/S1678-91992011000400008](https://doi.org/10.1590/S1678-91992011000400008)

Pardal PPO, Ishikawa EAY, Vierira JLF, Coelho JS, Dórea RCC, Abati PAM, Quiroga MMM & Chalkidis HM 2014 Clinical aspects of envenomation caused by *Tityus obscurus* (Gervais, 1843) in two distinct regions of Pará state, Brazilian Amazon basin: a prospective case series. – *Journal of Venomous Animals and Toxins including Tropical Diseases* 20(3): 1–7. – doi: [10.1186/1678-9199-20-3](https://doi.org/10.1186/1678-9199-20-3)

Pipalzadeha MH, Jalalib A, Tarazb M, Pourabbasb R & Zaremirkabadic A 2007 An epidemiological and a clinical study on scorpionism by the Iranian scorpion *Hemiscorpius lepturus*. – *Toxicon* 50: 984–992 – doi: [10.1016/j.toxicon.2007.07.018](https://doi.org/10.1016/j.toxicon.2007.07.018)

Polis GA 1990 The biology of scorpions. Stanford University Press, Stanford. 587 pp.

Reckziegel GC & Pinto VL Jr 2014 Scorpionism in Brazil in the years 2000 to 2012. – *Journal of Venomous Animals and Toxins including Tropical Diseases* 20(46): 1–8 – doi: [10.1186/1678-9199-20-46](https://doi.org/10.1186/1678-9199-20-46)

Watt DD & Simard JM 1984 Neurotoxic proteins in scorpion venom. – *Journal of Toxicology: Toxin Reviews* 3: 181–221 – doi: [10.3109/15569548409097925](https://doi.org/10.3109/15569548409097925)

Yağmur EA, Koç H & Kunt KB 2009 Description of a new species of *Leiurus* Ehrenberg, 1828 (Scorpiones: Buthidae) from southeastern Turkey. – *Euscorpius* 85: 1–20

Yağmur EA, Özkan Ö & Karaer KZ 2015 Determination of the median lethal dose and electrophoretic pattern of *Hottentotta saulcyi* (Scorpiones, Buthidae) scorpion venom. – *Journal of Arthropod-Borne Diseases* 9: 238–245

# ZOBODAT - [www.zobodat.at](http://www.zobodat.at)

Zoologisch-Botanische Datenbank/Zoological-Botanical Database

Digitale Literatur/Digital Literature

Zeitschrift/Journal: [Arachnologische Mitteilungen](#)

Jahr/Year: 2016

Band/Volume: [51](#)

Autor(en)/Author(s): Seiter Michael, Ullrich Alexander, Koc Halil, Yagmur Ersen

Artikel/Article: [The case history of a toxic sting of a Leiurus abdullahbayrami scorpion in Turkey 64-66](#)