

- SCHENKEL, R. (1966): Zum Problem der Territorialität und des Markierens bei Säugern — am Beispiel des Schwarzen Nashorns und des Löwen. *Z. Tierpsychol.* 23, 593—626.
- SCHENKEL, R.; LANG, E. M. (1969): Das Verhalten der Nashörner. *Handbuch der Zoologie* 8, Teil 10, Beitrag 25: 1—56.
- SCHLOETH, R. (1961): Das Sozialleben des Camarguerindes. *Z. Tierpsychol.* 18, 574—627.
- SCHNEIDER, K. M. (1930—1932): Das Flehmen I—IV. *Der Zoologische Garten (N. F.)* 3—5.
- VERBERNE, G. (1970): Beobachtungen und Versuche über das Flehmen katzenartiger Raubtiere. *Z. Tierpsychol.* 27, 807—827.

Anschriften der Verfasser: cand. phil. ULRICH HALDER, Zoologisches Institut der Universität Basel, Rheinsprung 9, 4000 Basel; Prof. Dr. RUDOLF SCHENKEL, Zoologisches Institut der Universität Basel, Rheinsprung 9, CH-4000 Basel

The Microscopic Anatomy of the Pineal Body of Impala (*Aepyceros melampus* Lichtenstein, 1812)

By W. M. MATHAI

Department of Veterinary Anatomy and Histology University of Nairobi, Nairobi, Kenya

Eingang des Ms. 29. 5. 1972

Introduction

The histological structure and cytology of mammalian pineal bodies is reviewed by QUAY (1965). Recently much work has been done on the mammalian pineal bodies especially as more evidence appears to confirm their functional significance as neuro-endocrine organs. Most of these investigations have been discussed by GUSEK (1968), REITER and FRASCHINI (1969), and WOLSTENHOLME and KNIGHT (1971).

The specific function of the mammalian pineal body remains to be elucidated. However, sufficient information is now available to show that this organ produces some biologically active metabolites which act on such areas as the reproductive and pigment-forming systems (HERBERT 1969; QUAY 1965, 1969b; ZADURA 1969; RUBIN 1971).

Materials and Methods

The present investigation was carried out in 12 adults impalas (*Aepycereos melampus* Lichtenstein, 1812). These are medium sized antelopes which thrive on semi arid bush and savannah grasslands of Central and Eastern Africa. The animals were shot on a private farm near Lake Elementeita at about 36° E and 0° S and 6000 ft. above sea level. Both the pineal bodies and the surrounding nerve tissue were removed and fixed in 10% formalin or in Bouin's solution.

Paraffin sections about 10 microns thick were cut and stained in Haematoxylin and Eosin, Goldner's stain for connective tissue and Bielschowsky's method for demonstrating reticular fibres. Frozen sections were cut and processed according to SCHROEDER, GROSSCHULTZE (ROMEIS 1968) and SCHAFFHALER and MAYERT (1957). Astrocytes were demonstrated using the goldmercuric chloride method according to RAMON Y CAJAL (ROMEIS 1968). To demonstrate both the oligodendroglia and the microglia, frozen sections were processed according to PENFIELD (ROMEIS 1968).

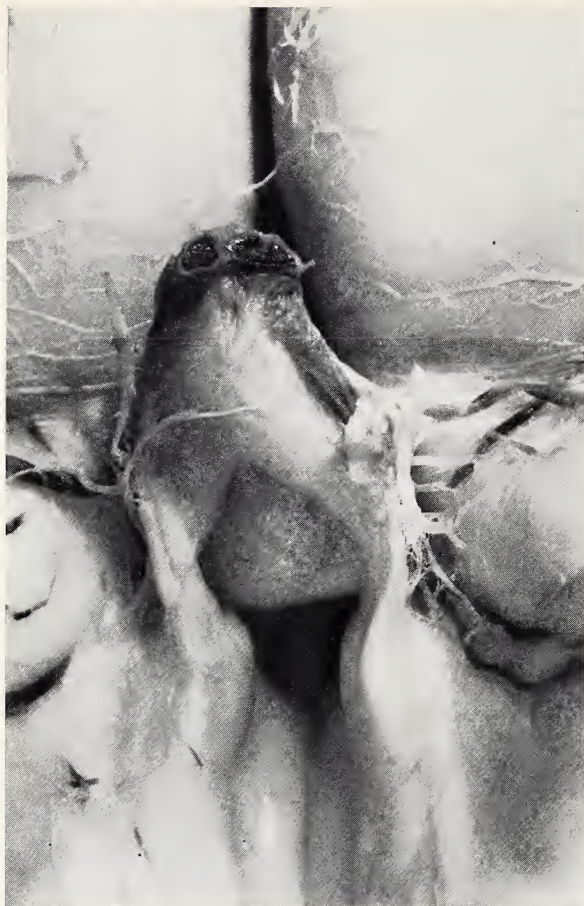


Fig. 1. The pineal body from an adult impala in situ. Note its topographic relationship to the neighbouring nerve tissue. Unstained (x 4.5)

Observations

The pineal body of adult impala is an ovoid body located medially between the habenular and the posterior commissures which also border it rostrally and posteriorly, respectively (Fig. 1). The apex of the pineal body is directed dorsocaudally while the base points ventro-rostrally. The choroid plexus of the third ventricle spreads over the apical surface of the pineal body and separates it from the roof of the skull (Fig. 2).

A recessus pinealis is present as a large central lumen. Sometimes this bears finger-like infoldings which extend deep into the pineal parenchyma. Its opening into the third ventricle is wide but usually tapers to a blind end a short distance just beyond the central area of the pineal.

A thin leptomeningeal capsule envelopes the free surface of the pineal except around the base and sends numerous septa into the underlying parenchyma. These septa subdivide the

pineal parenchyma into irregularly shaped but clearly delineated lobules. The latter are especially apparent in sections which are impregnated in silver carbonate solution according to PENFIELD.

The most predominant cells in the impala pineal are the pinealocytes. In sections stained with routine histological stains like Haematoxylin and Eosin, the pinealocytes show a uniform epithelioid appearance (Fig. 3). The cytoplasm of the pinealocyte is only slightly acidophilic. The general shape of the cells is spherical or angular with several cytoplasmic processes (Fig. 4). The cytoplasm forms a thin layer around the nuclei and is clearly visible in sections stained according to BIELSCHOWSKY. The nuclei of the pinealocytes are large and mostly spherical though ovoid nuclei are also present. These nuclei contain a moderate amount of heterochromatin and prominent nucleoli. The pinealocytes have no definite pattern although they may aggregate into small clusters in small areas. They are mostly randomly arranged with some areas being more densely populated with these cells than others.

Fibrous astrocytes are the next most predominant cells in the impala pineal. In sections impregnated with gold-mercuric chloride, they form an almost uninter-

rupted mass of processes extending haphazardly in every direction (Fig. 5). The processes are thick and branched. Some of them form foot plates on the walls of blood capillaries. In sections stained according to PENFIELD to demonstrate oligodendroglia and microglia, notably fewer astrocytic cells are scattered in the gold-mercuric chloride. The processes of these cells are shorter and are also observed to terminate on the walls of blood vessels. Apart from these apparently slight structural modifications, the astrocytes resemble the large, numerous fibrous astrocytes which are demonstrated according to CAJAL (Fig. 6).

The recessus pinealis in adult impala is lined by a simple layer of low ependymocytes. These cells typically send basal cytoplasmic projections into the underlying parenchyma for anchorage. Their free surfaces bear cilia.

Pineals of adult impalas have little connective tissue. Collagen fibres are confined to the thin capsule, capsular septa and walls of the larger blood vessels. A rich network of reticular fibres envelopes the numerous, small blood vessels in the parenchyma (Fig. 7). These reticular fibres are more numerous at the apical portion of the pineal than towards the base.

Branches of the cerebral magna enter the pineal at the apex (Figs. 1 and 7) and divide profusely in the pineal parenchyma (Fig. 8). Most of the blood vessels are located at the apical region. Only a few blood vessels appear at the basal area. A large vein drains and leaves the impala pineal at the apex and eventually enters the sagittal sinus.

A bundle of orthosympathetic myelinated nerve fibres enters the impala pineal at

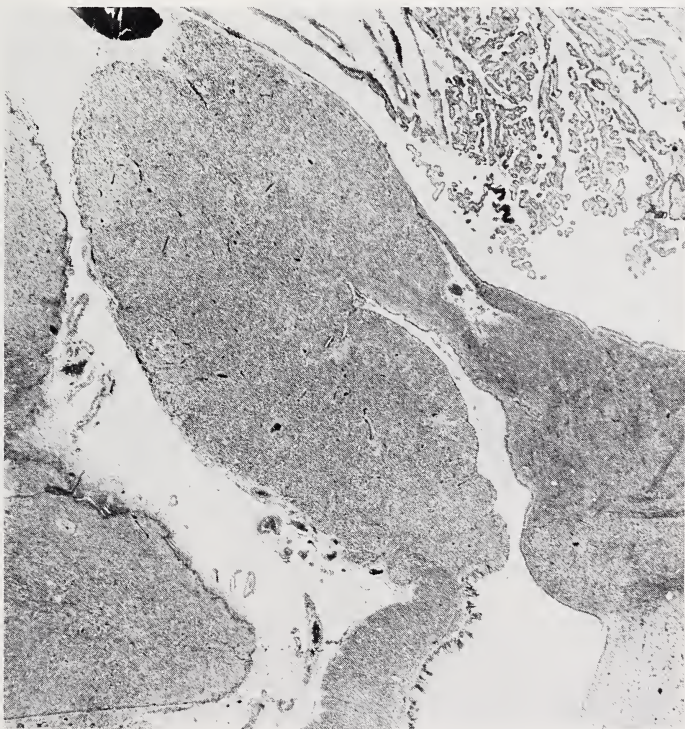


Fig. 2. A sagittal section through an adult impala pineal. Note the choroid plexus which extends over the apical surface of the pineal body. H and E (x 18)

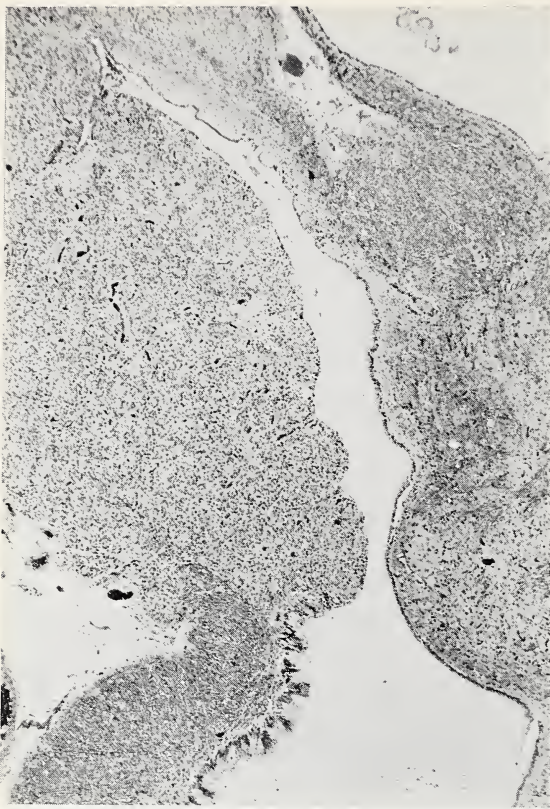


Fig. 3. A frontal section of a pineal body illustrating the uniform structure of the pinealocytes. Note the recessus pinealis. GOLDNER (x 40)

pineal parenchyma and in the thin leptomeningeal capsule. Acervuli were observed only in one pineal in the form of three to four spherical structures of a homogenous appearance.

Discussion

The topography and the histology of the adult impala pineal is characteristic of most mammalian pineal bodies. This is especially so in its medial location between the habenular and posterior commissures, its consolidated and gland-like structure, its cellular elements, manner of innervation and rich blood supply. These characteristics have been described in numerous works which are excellently summarised by QUAY (1965) and more recently by GUSEK (1968), REITER *et al.* (1969) and WOLSTENHOLME and KNIGHT (1971).

As in other mammals, the pinealocytes are the most dominant cell type in the pineal body of adult impala. These cells have a fairly uniform structure and staining affinities. With routine histological stains like Haematoxylin and Eosin, the general structure of these bodies is similar to that of epithelial tissue. As QUAY (1971) points out the implied assumption that there are only slight differences in the mammalian pineal bodies is probably only apparent. Electron microscopic works may in future provide more conclusive information. This is also true of the apparent epithelioid

the apex. This bundle runs along the large blood vessels of the pineal embedded in the surrounding connective tissue.

Numerous cerebral nerve fibres (myelinated and unmyelinated) also enter the pineal from the adjoining habenular and posterior commissures. They mostly run in bundles into and out of the pineal. Most of these fibres are located at the base where they haphazardly overcross and eventually re-join the respective commissure (Fig. 9). A large number of these fibres run from the base area and then parallel to the free surface of the pineal. At the apex, the fibres which are from the opposite sides of the commissure, overcross but continue their course to re-join the same commissure at the opposite side (Fig. 10). Some isolated fibres wind about in the pineal parenchyma but the majority always appear not to terminate in the pineal parenchyma but to re-join the other commissural fibres. Few fibres appear to terminate both in the

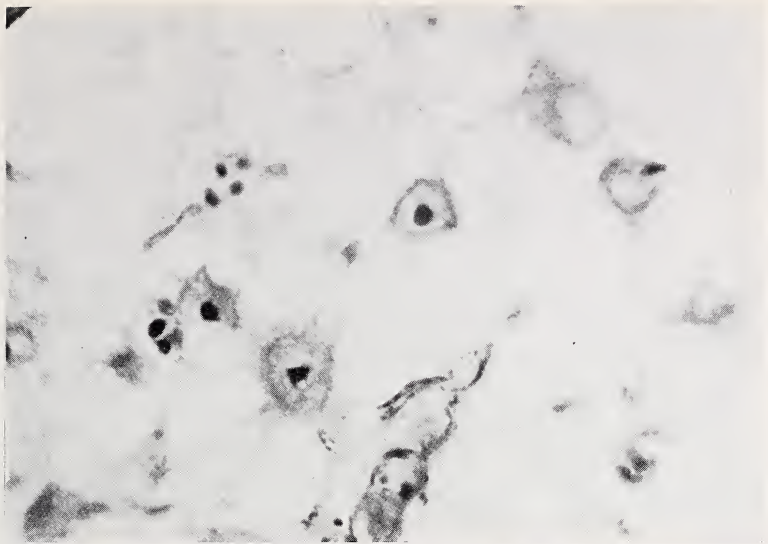


Fig. 4. Impala pineal showing pinealocytes with their cytoplasmic processes. BIELSCHOWSKY (x 1440)

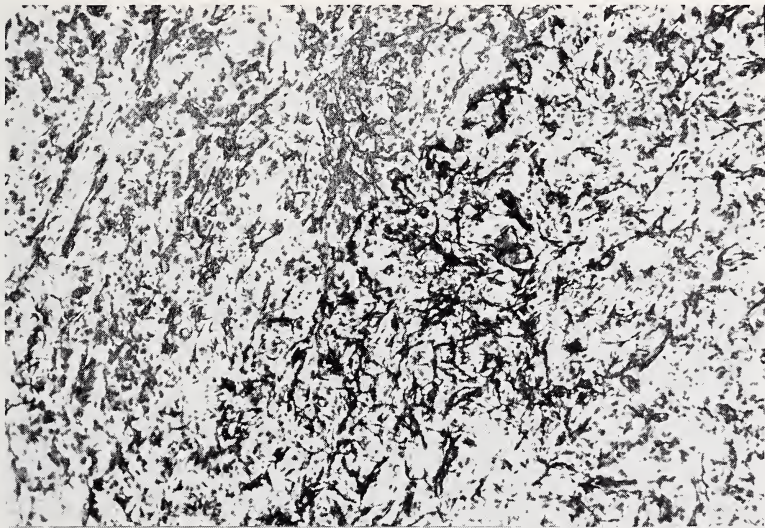


Fig. 5. A photomicrograph of a section of the pineal body. Note the numerous fibrous astrocytes. CAJAL (x 140)

character of the adult impala pineal where there may be more than one type of pinealocytes.

Neuroglia of astrocytic nature were clearly demonstrated in the impala pineal. These cell types have been repeatedly described in all mammalian pineal bodies as is clearly shown by QUAY (1965), and WOLSTEIN HOLME and KNIGHT (1971). They are also apparently much more numerous in the impala pineal than in the other mammals so far investigated. This is especially so when sections are treated with gold-mercuric

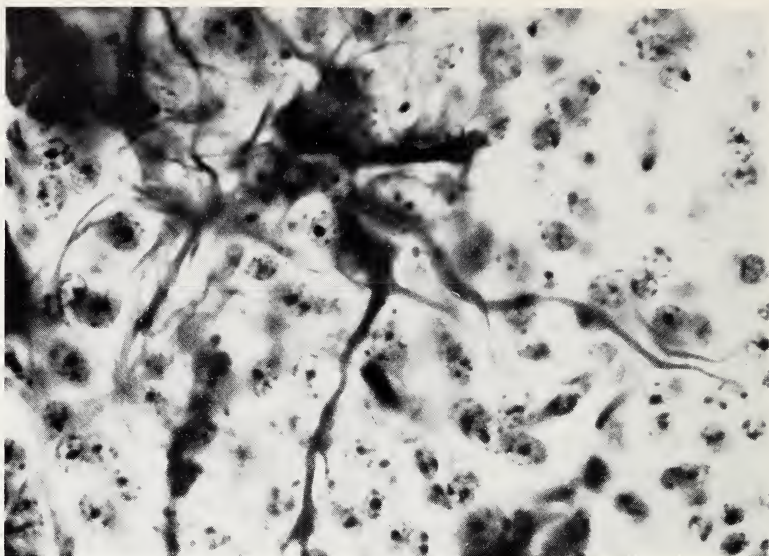
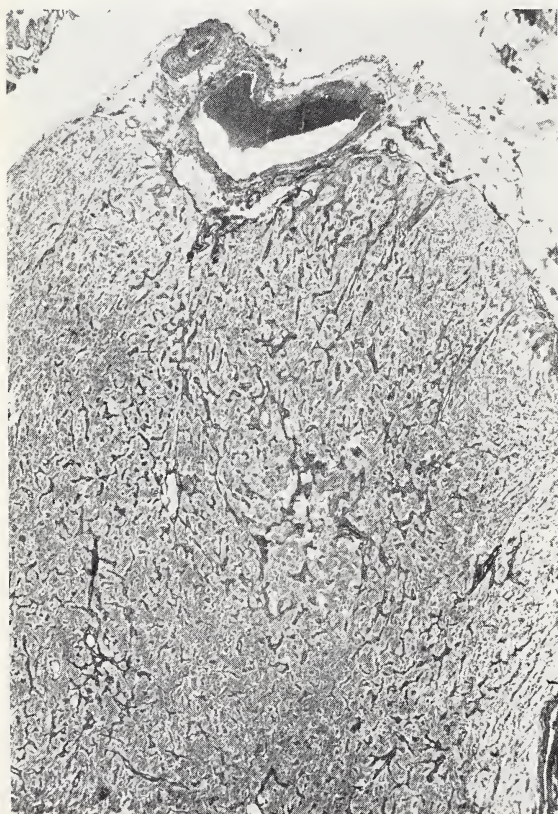


Fig. 6. Sections treated according to PENFIELD for oligodendroglia and microglia. See discussion (x 570)



chloride. The cells which react positively to PENFIELD's method for oligodendroglia and microglia are structurally similar to the other astrocytic cells which are demonstrated according to CAJAL's method using mercuric-chloride. Therefore, it seems very probable that both groups are functionally identical.

Numerous cerebral nerve fibres are found in the impala pineal parenchyma. KAPPERS (1960) has shown that these fibres are drawn into the pineal during the embryonic development of this body and that the fibres leave the pineal again. They may, however as he points out (KAPPERS 1960, 1969) also terminate aberrantly in the pineal. The mammalian pineal body is however innervated by

Fig. 7. A photomicrograph through the apical portion of a pineal body. Note the numerous reticular fibres and the two main blood vessel.

BIELSCHOWSKY (x 40)

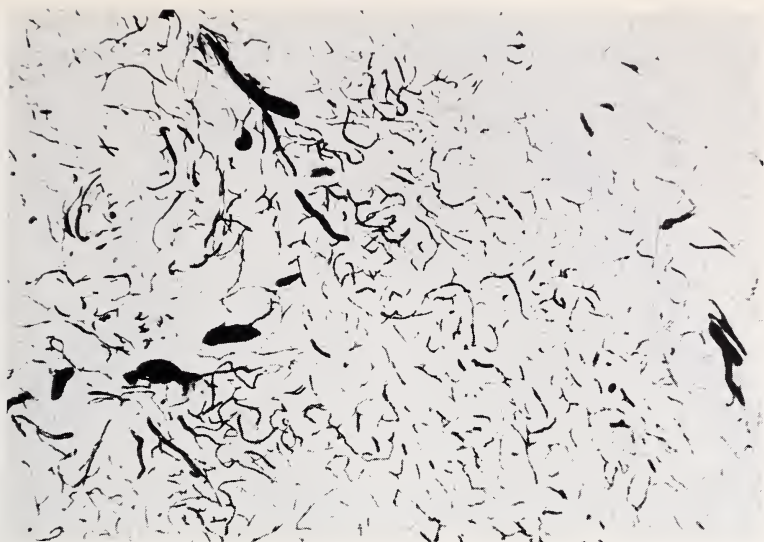


Fig. 8. In this photomicrograph there are numerous blood vessels supplying the pineal parenchyma. SCHROEDER (x 8)



Fig. 9. A photomicrograph of a frontal section through the base of an impala pineal showing commissural myelinated nerve fibres. SCHROEDER (x 35)

sympathetic nerve fibres from the cervical ganglia. These fibres enter the pineal at the apex along with the blood vessels and they are myelinated (KAPPERS 1960, 1969).

The blood supply of the impala pineal body also corresponds to what has been described in other mammals by several investigations like QUAY (1958, 1965) and REITER et al. (1969). Such ample blood supply is characteristic of mammalian pineal bodies and in endocrine organs in general. This observation supports the general



Fig. 10. In this photomicrograph, through the apical portion of an impala pineal, commissural myelinated nerve fibres are observed. Sagittal section. SCHROEDER (x 35)

assumption that the mammalian pineal body synthesizes some biologically active metabolites and releases them directly into the blood stream.

It should also be noted that neither muscle fibres nor lymphatic tissue is observed in any of the impala pineals. Connective tissue is characteristically present in small amounts and is mostly confined to the walls of blood vessels, the capsule and septa.

Acknowledgements

I am thankful to Professor R. R. HOFMANN for his help in collecting the materials and also to Professor P. WALTER for giving me the facilities to do the initial part of this work in his Department.

Summary

The pineal bodies of 12 adult impalas (medium sized antelopes) were studied with light microscopy. The results revealed a moderately large, consolidated organ amply supplied with blood vessels and nerve fibres. Both topographically and histologically the pineal body of impala resemble that of most mammalian pineal bodies.

Zusammenfassung

Es wurden zwölf Zirbeldrüsen von erwachsenen Impalas (Antilopen mittlerer Größe) lichtmikroskopisch untersucht. Diese Organe sind mäßig groß und reichlich mit Blutgefäßen und Nerven versorgt. Die Topographie und Histologie der Impalazirbeldrüse ähnelt den meisten Säugetierzirbeldrüsen.

References

- GLADSTONE, R. J.; WAKELEY, C. P. G. (1940): The Pineal Organ. Williams and Wilkins Company, Baltimore.
- GUSEK, W. (1968): Neue Befunde zur Morphologie und Funktion der Epiphysis cerebri. *Ergeb. allg. Path. path. Anat.* **50**, 103—148.
- HERBERT, J. (1969): The pineal gland and light induced oestrus in ferrets. *J. Endocrinology* **43**, 625—636.
- KAPPERS, A. J. (1960): The development, topographical relations and innervations of the epiphysis cerebri in the albino rat. *Z. Zellforsch.* **52**, 163—215.
- (1969): The mammalian pineal organ. *J. Neuro-Visceral Relations*, **9** (suppl.), 140—184.
- KENNY, C. C. T. (1965): Transversely striated muscle fibres in the pineal region of mammals. *J. Anat.* **99**, 945.
- MESS, B. (1968): Endocrine and neurochemical aspects of pineal function. *Int. Rev. Neurobiol.* **11**, 171—198.
- MIKAMI, S. (1951): Cytological and histochemical studies of the pineal bodies of domestic animals. *Tohoku J. Agricult. Res.* **2**, 21—48.
- QUAY, W. B. (1957): Cytochemistry of pineal lipids in rat and man. *J. Histochem. Cytochem.* **5**, 145—153.
- (1958): Pineal blood content and its experimental modification. *Amer. J. Physiol.* **195**, 87—100.
- (1959): Striated muscle in the mammalian pineal organ. *Anat. Rec.* **133**, 57—63.
- (1965): Histological structure and cytology of the Pineal Organ in Birds and Mammals. *Progress in Brain Research* **10**, 49—86.
- (1969b): Evidence for a pineal contribution in the regulation of vertebrate reproductive systems. *Gen. Comp. Endocri.* **2**, (suppl.), 101—110.
- (1971): Organization and histology of the pineal region in the hyrax (*Procavia capensis*). *Amer. J. Anat.* **130**, 377—392.
- REITER, R. J.; FRASCHINI, F. (1969): Endocrine aspects of the mammalian pineal gland: A Review. *Neuroendocrinology* **5**, 219—255.
- RUBIN, B. D.; TRAUM, R. E. (1971): The effect of melatonin on ovarian compensatory hypertrophy in the rat. *J. Endocrinology* **50**, 179—180.
- WISLOCKI, G. B.; DEMPSEY, E. W. (1948): The chemical histology and cytology of the pineal body and neurohypophysis. *Endocrinology* **42**, 56—72.
- WOLSTENHOLME, G. E.; KNIGHT, JULIE (1971): Ciba foundation Symposium. The pineal gland. Churchill, Livingstone. Edinburgh. Scotland.
- ZADURA, J.; ROSZKOWSKI, JACEK; CAKALA, STANISLAW (1969): The effect of pinealectomy on weight and histological changes of testes and adrenals of cockerels. *Bull. Vet. Inst. Pulawy* **11**, 140—143.

Author's address: Dr. W. M. MATHAI, Department of Veterinary Anatomy and Histology, University of Nairobi, P. O. Box 30197, Nairobi, Kenya

ZOBODAT - www.zobodat.at

Zoologisch-Botanische Datenbank/Zoological-Botanical Database

Digitale Literatur/Digital Literature

Zeitschrift/Journal: [Mammalian Biology \(früher Zeitschrift für Säugetierkunde\)](#)

Jahr/Year: 1971

Band/Volume: [37](#)

Autor(en)/Author(s): Mathai Wangari M.

Artikel/Article: [The Microscopic Anatomy of the Pineal Body of Impala \(*Aepyceros melampus* Lichtenstein, 1812\) 245-253](#)