

- (1972): Capture, laboratory care and breeding of Elephant-Shrews (Macroscelididae). *Laboratory Animals* 6, 213—224.
- VAN VALEN, L. (1967): New Paleocene insectivores and insectivore classification. *Bull. Amer. Mus. Nat. Hist.* 135, 218—284.
- WINGE, H. (1941): The interrelationships of the mammalian genera. II. Rodentia, Carnivora, Primates. Copenhagen: Reitzel.
- WYNNE-EDWARDS, V. C. (1962): Animal Dispersion in relation to social behaviour. Edinburgh: Oliver and Boyd.

Anschrift des Verfassers: Prof. Dr. E. G. F. SAUER, Zoolog. Forschungsinstitut u. Museum A. Koenig, D 53 Bonn 1, Adenauerallee 150—164.

On the Topography and Structure of the so-called Glandular Subauricular Patch and the Inguinal Gland in the Reedbuck (*Redunca arundinum*)

By CLAUS-PETER CLAUSSEN and HARTMUT JUNGIUS¹

From the Institut für Haustierkunde der Universität Kiel

Director: Prof. Dr. Dr. h. c. W. Herre

Receipt of Ms. 30. 5. 1972

Introduction

In the literature on the comparative anatomy of subcutaneous glands (SCHAFFER 1940; VON SCHUMACHER 1943), only contradictory information is found on the distribution, structure and function of the so-called glandular sub-auricular patch (auricular patch, juxtaauricular organ, *Unterohrdrüse*) in antelopes. This applies also to the inguinal glands (inguinal pockets). The aim of this study is to clarify the topography and structure of these glands by means of macroscopic and histological investigations within one antelope species, the reedbuck.

In Table 1, distribution, biotope and some biological characteristics of the reedbuck are summed up. For more details on the species see JUNGIUS (1970, 1971a, 1971b).

R. arundinum is bigger than all other reedbuck species: rams have a shoulder height from 80 cm to 105 cm and females from 65 cm to 95 cm (HALTENORTH 1963).

The general colour varies between dark brown, greyish brown and a light yellow brown. The upper sides of the neck, head and tail are always lighter in colour than the back. Only the belly and the underside of the tail are white, whereas the inner sides of the legs and the underside of the neck are greyish white. The frontlegs have a dark brown vertical stripe. Horns are only found on the rams. The tips of the horns are curved forward. Permanent rings show two-thirds from the base of the horns. At

¹ Material, macroscopical, and ethological investigations have been issued by this author.

the base of the horns are soft half-moon shaped enlargements (Wülste), which often look white because small pieces of horn material are constantly breaking off. From personal observations it can be stated that these soft enlargements are already formed during the first years.

Table 1

Distribution, biotope, and some important biological characteristics of *Redunca arundinum*

Range	Biotope	Some biological characteristics
<p><i>Africa</i> south of the Equator. From south-west Gaboon (about 3° latitude south) and from southern Tanzania (about 9° latitude south) southward to the western parts of the Cape Province, South Africa. Excluding the densely forested Congo basin and the dry areas of the western Cape Province, Botswana and S.W. Africa (ANSELL 1968; HALTENORTH 1963).</p>	<p>Long grass savanna, open tree savanna, vleis (see below), if water is available, all year round. Forests, bush, steppe and dry areas are avoided.</p>	<p><i>Social behaviour:</i> Reedbucks live in territories (established by a ♂) in pairs, mother/families (♀ and fawn, fawns are born throughout the year. They are "Ablieger", which means they are hidden away for 2—3 months), ♂-mother/family (♂ with ♀ and fawn). No formation of herds. Only in the dry season concentrations of more than three animals occur around water holes or in grazing areas. R. do not easily associate with other species. Distinct nocturnal habits during seasons with good food supply, with the onset of dry season extension of activity into the morning and late afternoon. R. are unpretentious grazers. (JUNGIUS 1971b).</p>
<p><i>KNP</i> Wide spread insular distribution. Particularly common in the long grass veld of the Pretoriuskop section, the northern Lebombo flats and the Mlondose headwaters of the central district. Common in most vleis of the northern Mopaneveld (PIENAAR 1963).</p>	<p>Long grass savanna and tree savanna, slopes with tall grass (<i>Hyparrhenia dissoluta</i>), along small rivers, in vleis (shallow and poorly drained grassy valleys which are inundated during the rainy season. <i>Sporobolus robustus</i> is the dominant grass).</p>	<p><i>Adaptation to environment:</i> Reedbucks are well adapted to living in tall grass. This offers cover and food, but makes orientation more difficult. From this, two essential behaviour patterns may have developed. — Avoidance of predators. Freezing (motionless watching), short escape distances. Living down and sneaking off. The reedbuck prefers hiding to escape, like other species living in dense cover. — Running with high bounding jumps and upright neck to keep their bearings is characteristic of R. From these and other behaviour patterns (JUNGIUS 1971a) it can be concluded that <i>R. arundinum</i> is an intermediate type between antelope species living in dense cover like duiker and bushbuck (so-called "schlüpfer", KRIEG 1936) and those of the open grasslands (JUNGIUS 1971a).</p>

Material and methods

The histological examinations were carried out on material obtained from animals from the Kruger National Park (KNP). The skin samples were taken from 7 healthy animals immediately after they had been killed by predators or died as a result of shooting. The treatment of the samples (fixed in a 4% formalin solution), followed the usual method with methylbenzoate, methylbenzoate-celoidin (PETERFI) and benzol in paraffin. The 10 μ paraffin sections were cut in two planes : transversely and longitudinally.

Various stains such as Haematoxylin-Eosin, "one step trichrome" (GOMORI), Masson Trichrom stain, Goldner's modification of Masson Trichrom stain, Weigert's elastic stain (MOORE) and silver impregnation (BODIAN) were used.

Examination of the stained sections was done with LEITZ-Ortholux and by means of microphotographs taken with LEITZ-Orthomat and AGFA-Film (15 Din panchromatic). In the sizes given for the tissues and cells shrinkage resulting from microtechnical preparation has not been taken into account.

I. Topography and macroscopical anatomy of the glandular auricular patch and the inguinal gland

1. The auricular patch

In all adult reedbucks of the KNP the auricular patch is a distinct, black, almost hairless patch of skin, under the auricle near the base of the ear (figs. 1 and 2). This dark patch is well developed in rams and females.

It is absent in young animals during their first months of life. The area of the auricular patch can only be distinguished from the other skin because of its lighter



Fig. 1. Position of the glandular subauricular patch in *R. arundinum*. ♀ about 18 months old

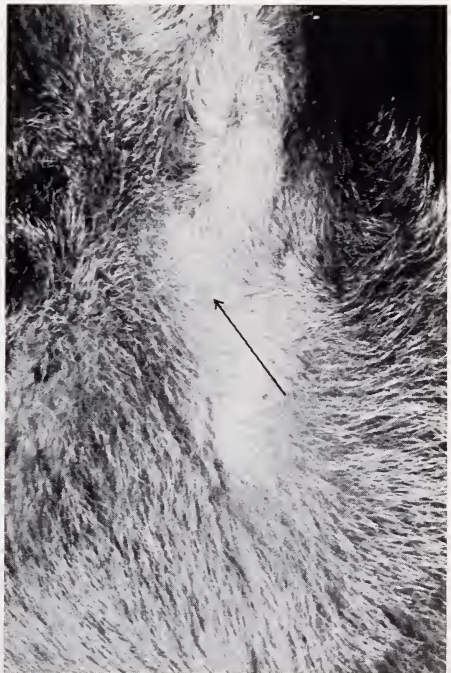


Fig. 3. Glandular subauricular patch of a 14 days old fawn, thickly covered with hair

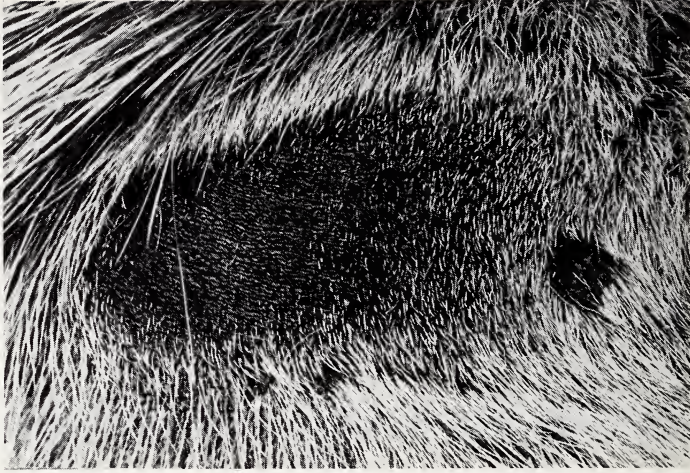

Fig. 2. Glandular subauricular patch of an adult ♂, sparsely covered with hair

colour and shorter hairs, as shown in figure 3 of a 14 days old fawn. According to field observations it can be assumed that the loss of hair in the gland area starts within the seventh or eighth month after birth (fig. 4). This process seems to come to an end at the age of one year when young animals show the adult condition (fig. 5 and 2). From now on the patch increases in size only.

In adult animals the size of this patch varies considerably. In a selection of five animals the total length was between 2.8 and 4.2 cm and the largest width was between 1.2 and 3.2 cm. The juxtaauricular organs are absent in some reedbuck populations outside the KNP. For instance, observations of a large reedbuck concentration in Rhodesia at Kyle Dam (near Fort Victoria) revealed no naked glandular area under the ear. The ranger, T. BRAYBROOKE, confirmed this regarding all reedbuck which he had seen, with a reservation that in some cases there is "a thinning of

hair at this spot . . . on some reedbuck, but this can only be seen from very close observation".

On one of his photographs, a distinct grey hairy patch can be seen in this area, in the centre of which dark skin shines through (fig. 6).

Even in reedbucks of the highveld of East and West Transvaal, the large, dark, nearly bare glandular patch under the ear seems to be missing (E. YOUNG 1968, pers. com.). This distinct patch was also missing in two of the reedbuck in the



Fig. 4. The thick covering of hair starts to disappear in a 7 to 8 months old fawn




Fig. 5 (left). The dark auricular patch is distinctly visible in young ♂ (about 1½ years old). In the lower parts the horn is surrounded by young horn (Jugendhorn) — Fig. 6 (right). Adult ♂ from Rhodesia (Kyle Dam). The glandular subauricular patch is thickly covered with fine hair. (photo by BRAYBROOK)

Zoo in Pretoria which came from the Rustenburg area (BRANDT 1968, pers. com.). The ram in the zoo showed this to a lesser extent, but it was obvious that the hair in the glandular area was getting thinner towards the centre so that the skin beneath appeared to shine through, (similar to those from Rhodesia). In the female this area was completely covered with fine, short grey hair. This stood out in comparison with the surrounding fur which is yellowish-brown and much longer.

In some animals from a large population in the Umfolozi Game Reserve (Natal) a nearly bare patch was present but it seemed much smaller than the one described for animals in the KNP. The hair cover resembles the patches seen in animals from the Transvaal. Frequently a distinct patch was totally missing.

Table 2

No. of adult reedbucks observed at Umfolozi	Sex	No. of reedbuck with a distinct glandular patch
9	♂	2
11	♀	10

Because the number of observed animals was so small, the evidence of sexual dimorphism could not be decided. But from the foregoing, it can be concluded that the development of the auricular patch varies widely in reedbuck.

2. The inguinal glands

The inguinal glands (inguinal pockets, inguinal glandular pockets) of *Redunca arundinum* in the KNP occur in pairs and are situated in the inguinal region. Rams have only one pair of these glands whereas the one female examined had two pairs, one big and one small. The glands on one side of the body of this doe were separated by a wall of skin (fig. 7). The low reedbuck population in the Park did not permit the trapping of more females for examination. Nevertheless the statement by HALTENORTH

(1963) that *R. arundinum* generally has only one pair of glands, should perhaps, be re-considered.

The inguinal glands in all reedbucks examined showed that they are blind pockets. They are conical and have a funnel shaped orifice. On the outer rims of these funnels, which are nearly round in ♂♂ and which are oval in the ♀, a varying amount of a yellow waxy secretion accumulates in the form of lumps. Some lumps are so large that the

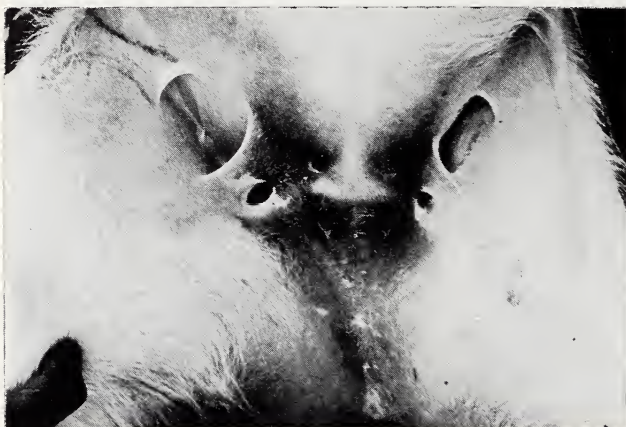

Fig. 7. Pockets of the inguinal glands in a ♀ from the KNP, about 18 months old

opening of a gland seems to be totally obstructed. Similar observations are recorded on the Uganda Kob (BUECHNER et. al. 1965). In the one ♀, exceptionally large amounts of secretion were found in the smaller inguinal pockets. The secretion itself has a pungent odour.

The inner parts of the orifice are fine and sparsely covered with hair. The following measurements were made on animals in the KNP.

Table 3

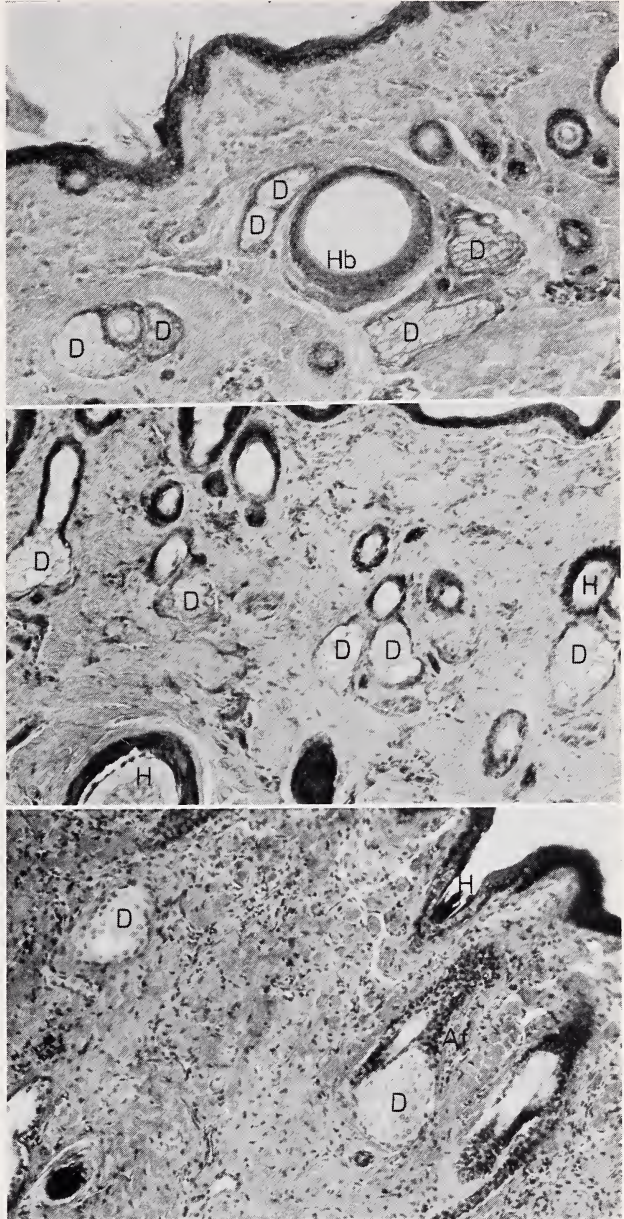
No. of checked animals	Sex	No. of inguinal glands a. shape of orifice	Diameter of the orifice	Depth of the inguinal pocket
3	♂	one pair, round	4—5 cm	7.5—10.0 cm
1	♀	2 pairs, oval 1 smaller pair 1 larger pair	1.5 x 0.5 cm 1.4 x 2.8 cm	2.8 cm 2.8 cm

II. Microscopical anatomy of the glandular subauricular patch and of the inguinal gland

1. The glandular subauricular patch

The glandular subauricular patch of the reedbuck represents an accumulation of extremely enlarged sebaceous glands, (gll. sebaceae) in a confined skin area. They are

Fig. 8 a-c. Survey: Auricular patch in different cutting positions — a (above). Transversal section: Gll. sebaceae around hair follicles. Hairs are partly fallen out (artefacts). H.-E., 120 x — b (middle). Slant section: Gll. sebaceae with some mature cells (vacuoles). H.-E., 120 x — c (below). Longitudinal section: Sebaceous gland with the entrance to the excretory duct. H.-E., 120 x · D = sebaceous gland, Af = excretory duct, H = hair, Hb = hair follicle



more or less irregularly scattered in the upper parts of the stratum reticulare of the corium. These glands always run into the funnel of the hair of one hair follicle, usually just below the epidermis in the stratum papillare (fig. 8, 9, 10). These sebaceous glands are closely linked with the hair follicle and are oval to cone shaped. Their excretory ducts seem to be rather short and are coated with a stratified squamous epithelium (continuation of the outer sheath of the hair follicle), which is gradually leading over to the epithelium of glands. An accurate line between the corpus of the sebaceous glands and the excretory duct can consequently not be clearly defined. The length

of these sebaceous glands in the tissue sections amounts to 67μ , and the greatest width (133μ) is at the base. Compared with adjacent skin parts, it shows that these hairs, which originate from the sebaceous glands are greatly reduced in size, or even missing. These gll. sebaceae are holocrine glands. They consist of a multilayered glandular epithelium in which the lumen is missing. A basal cell layer situated on a basal membrane contains no visible fat vacuoles. This is followed by several cell layers showing vacuoles.

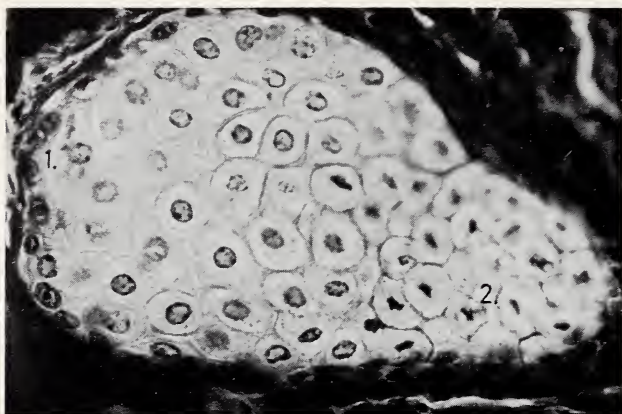
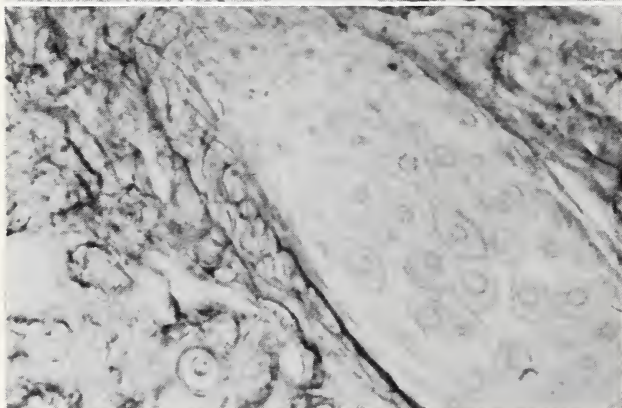
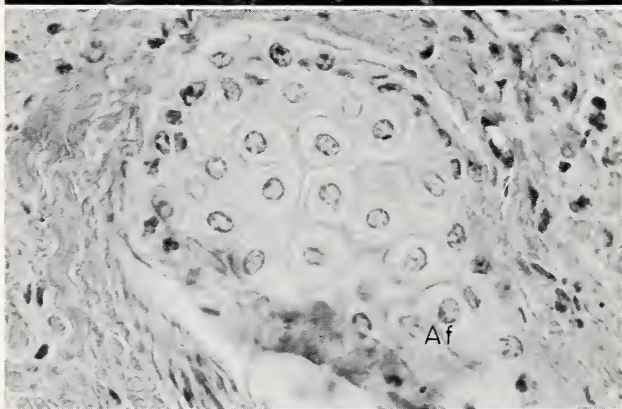


Fig. 9 (above). Auricular patch: Sebaceous gland with different stages of maturity of the cells. Masson, 480 x. 1. = basic cells (substitute cells), 2. = mature cells with pycnotic nuclei — Fig. 10 (middle). Auricular patch: Sebaceous gland with different stages of maturity of the cells and with the entrance to an excretory duct. Af = excretory duct. H.-E., 480 x — Fig. 11 (below). Auricular patch: Elastic fibres around a sebaceous gland. WEIGERT'S Elastic stain (MOORE), 480 x



The basal cells of the sebaceous glands are flat to cuboidal in shape. They have relatively large nuclei corresponding in shape to that of the cells, and frequently containing a distinct nucleolus. From this peripheral glandular epithelium the physiological regeneration of the sebaceous glands seems to take place, because in some tissue sections sporadic mitosis has been observed. The basal cells seem to be a kind of “substitute cells” for the permanent growth process of the glandular cells (SCHAFER 1940; NEUBERT 1930; MONTAGNA/KENYON 1949; MONTAGNA 1952; HORSTMANN 1957; WIENKER 1968). A replacement of the sebaceous glands start-

ing with the excretory ducts, as described by some authors (BRINKMANN 1911; CLARA 1929; SIMPSON/CRAMER 1943, 1945; MONTAGNA/NOBACK 1946) does not appear to take place in the glandular subauricular patch of *Redunca arundinum*. The glandular cells of the following layers, as well as their fat vacuoles increase steadily in size. Towards the centre of the so-called mature cells, which are mostly filled with sebum an which are directed toward the excretory duct, the vacuoles have already grown so much in size, that they are only separated by narrow cytoplasmic septa. Simultaneously this process of vacuolisation (sebum forming) is linked with a pyknosis of the

nucleus. Eventually the nucleus falls apart and the cellular limits disappear, while the cytoplasm is mixed with the sebum secretion. Around these sebaceous glands many collagenous fibres are situated. Elastic fibres form a narrow, but very dense reticular covering (fig. 11). Apart from this isolated fibrocytes are to be found around these cells. They are particularly noticeable because of their widely spread cytoplasm. If the sebaceous glands border with the *m. arrector pili*, only few collagenous fibres separate the muscle from the gland. Several arteries and capillaries nearly always occur near the sebaceous glands. They come very close to the periphery of the gland epithelium. We did not succeed in tracing nerve fibres in either the gland or the surrounding connective tissue.

2. The inguinal glands

The microscopical anatomy of the inguinal glands of *Redunca arundinum*, corresponds in general with the glandular subauricular patch (fig. 12). They also represent an accumulation of oval to cone shaped non-ramified sebaceous glands with a relatively short excretory duct (fig. 13). They are of similar histological structure and show the same type of holocrine mechanism of secretion as the auricular patch. The only difference between the two types of skin gland lies in the considerably smaller number of single sebaceous glands per area occurring in the inguinal gland.

According to our investigations, in most cases one or two sebaceous glands run into the funnel of the hair of each hair follicle. Apocrine glands which are said to lie under these sebaceous glands in the inguinal glands of the sheep (SCHAFER 1940) could not be observed in *Redunca arundinum*.

III. Discussion

The glandular auricular patch of *R. arundinum* belongs to the juxtaauricular organs (SCHAFER 1940) which are also present in the oribi, pronghorn, waterbuck and lemming (DOLLMANN 1931; SCHAFER 1940). According to our histological

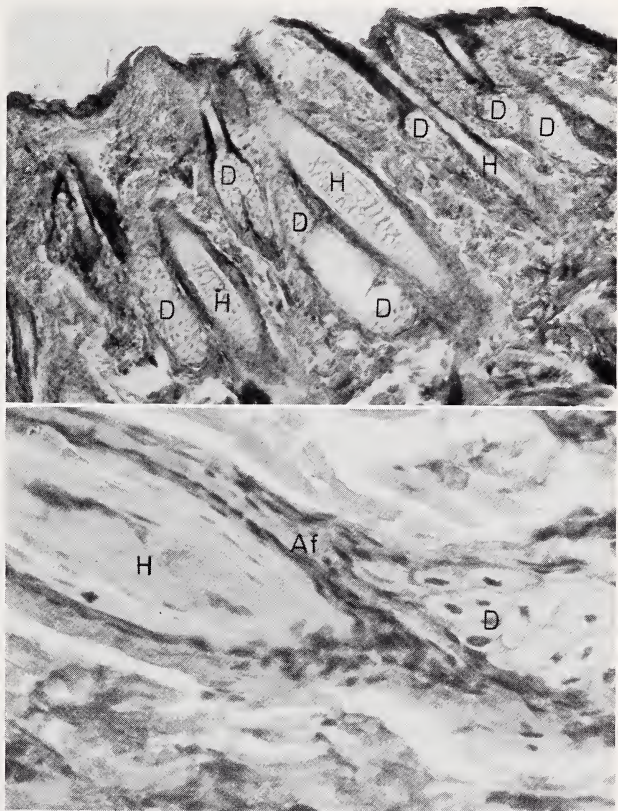


Fig. 12 (above). Survey: Inguinal gland, longitudinal. H.-E., 120 x. D = sebaceous gland, H = hair — Fig. 13 (below). Inguinal gland: Sebaceous gland with excretory duct. H.-E., 480 x. Af = excretory duct, D = gland, H = hair

findings in *R. arundinum*, these organs represent an accumulation of enlarged sebaceous glands which produce secretion of the holocrine type. During field observations no distinct visible secretion could be seen.

The inguinal glands or inguinal pockets, which look like baggy invaginations are found in sheep and among antelopes in: duikers, oribi, some *Tragelaphus* species, many gazelles and some Reduncini for instance *R. recunca*, *R. fulvorufula*, *R. arundinum* (SCHAFER 1940; HALTENORTH 1963). The inguinal gland of these species, as well as the auricular patch (cited above) represents an accumulation of holocrine sebaceous glands. Unlike the auricular patch the secretion of these glands is macroscopically visible. Biologically the auricular patch and the inguinal glands of *R. arundinum* seem to play an important part in social behaviour.

1. Marking of territories

Defence of boundaries and marking activities are essential parts of the behaviour of territorial species (HEDIGER 1949). Apart from optical and acoustical means, olfactorical methods are applied first (HEDIGER 1949).

Scent marking can occur directly. For instance the glandular secretion of the pre-orbital glands in gazelles, duikers and Neotragini, is wiped off on branches or on other projecting objects (HEDIGER 1949; ZIEGLER/SIMON 1957; RAHM 1960; DIETRICH 1965; WALTHER 1968). Scent marking also occurs indirectly, for instance the distribution of secretion produced by the interdigital glands of several ungulate species. In both cases, scent marks are left. In this way, particularly members of the same species are informed that an individual of the species is present or that the area is occupied by it.

Direct scent marking with the auricular patch or the inguinal gland was never observed in the reedbuck. In reedbuck territories a scattered scent distribution seems to take place. However, we are left to guess how this distribution is carried out. The invisible products of the auricular patch can be wiped off by walking through the tall grass (Table 1), or during grazing. When scratching the auricular patch, secretion may get to the hoof from where it is distributed to the ground (similar in *Alcelaphus buselaphus lelwel*, BACKHAUS 1959). It can also be transferred to the body by rubbing the head against a particular spot (grooming behaviour), from here it can be wiped off by walking through the grass or when resting. The visible products of the inguinal glands can also fall off and remain in the bedding area. Small parts of secretion may also be wiped off the orifice of the gland by tall grass when the animal is walking. It is also possible that small amounts of sebum fall off during a particular flight behaviour. Sometimes the animals produce a clapping sound by exaggerating the throw up of their hindlegs and at the same time kicking sideways. We suppose that the walls of the inguinal glands stick together (caused by secretion) and seemingly by this motion, they get opened and produce this sound. With this action sebum particles may fall off and leave a scent mark. Another distribution of secretion can take place by licking the glandular area. The tongue carries the scent to other parts of the body from where it is transmitted to the environment.

2. Glandular subauricular patch and inguinal glands are important means of communication within reedbuck pairs and families

As the habitat has good coverage and dense vegetation pairs of reedbucks or members of a family are sometimes separated from each other for half a day or even a day. Visual contact between the animals is very difficult due to the long grass, therefore acoustical and olfactorical means of communication are very significant, and in this connection the products of the auricular patch and the inguinal gland may play an

essential part. Occasionally rams have been observed walking slowly through their territory with their head bent down and sometimes even stopping to sniff at grasses before continuing to walk on. The destination of these walking tours was either a resting ♀ or another ♂. This behaviour corresponds to some extent with the well known behaviour pattern of the roe deer ♂ when following the scent trail of a ♀ during the mating season (KURT 1968). Significance of both glands during mating behaviour and during contact between ♂ and ♀ has not been observed. Inguinal nuzzling of the ♀ by the ♂, poking and stroking of the inguinal region of the ♀ by the ♂ with the horns during the mating activity, as described in the Uganda Kob by BUECHNER and SCHLOETH (1965) has not been observed in *Redunca arundinum*.

Acknowledgements

Grateful acknowledgement is made to the Deutscher Akademischer Austauschdienst and the Deutsche Forschungsgemeinschaft for financing this study and to the Director of the National Parks Board of South Africa, Mr. R. KNOBEL and to the late Deputy Director, Mr. R. J. LABUSCHAGNE who provided the necessary study facilities within the Kruger National Park. Thanks are also expressed to Dr. U. de V. PIENAAR and Mr. P. VAN WYK, biologists from Skukuza who assisted with their advice and experience and to the Deputy Director of the National Parks Board Mr. A. M. BRYNARD, Dr. J. MEESTER and Prof. Dr. F. C. ELOFF from the University of Pretoria for their helpful support.

Summary

The presence, topography, the macroscopic and the microscopic anatomy of the so-called glandular subauricular patch (juxtauricular organ or auricular patch) and of the inguinal gland (inguinal pockets) of the reedbuck (*R. arundinum*) have been examined.

1. The *glandular subauricular* patch is very obvious in all adult reedbuck from the KNP and some from the Umfolozi Game Reserve. It seems to be less distinctly developed in reedbuck of East and West Transvaal, those from the Kyle Dam (Rhodesia), and some from Umfolozi. In the reedbuck of the KNP and some of Umfolozi Game Reserve the auricular patch is a distinct black, sparsely haired nearly bare skin patch under the ear. In reedbuck from Kyle Dam, some from Umfolozi and the Transvaal, the glandular area is not so distinctly visible, but more or less thickly covered with short thin hair, only sometimes, near the center, black skin seems to shine through. From the histological point of view this gland represents an accumulation of single undivided, extremely enlarged sebaceous glands (gll. sebaceae) which produce their secretion in the holocrine type.
2. The *inguinal glands* of *R. arundinum* in the KNP always occur in pairs. They are blind pockets, nearly hairless, conically shaped and have a funnel shaped orifice. The extremely enlarged holocrine sebaceous glands correspond largely with those of the subauricular patch. But their secretion is distinctly visible and of a pungent odour.
3. The auricular patch and the inguinal gland of *R. arundinum* seem to be of great importance in social behaviour.
 - a. They are means for territory-marking.
 - b. They are important for communications within pairs or families, and with other redbucks.

Any significance of these glands in the behaviour pattern of pre-mating, mating or post-mating has not been observed.

Zusammenfassung

Über die Topographie und den Bau der sogenannten „Unterohrdrüse“ und der Inguinaldrüsen des Riedbocks (Redunca arundinum)

Das Vorkommen, die Topographie und die makroskopische sowie die mikroskopische Anatomie der sogenannten „Unterohrdrüsen“ (= Juxtauricularorgane) und der Inguinaldrüsen (Inguinaltaschen) des Riedbocks (*Redunca arundinum*) wurden untersucht:

1. Die „Unterohrdrüsen“ sind deutlich bei allen adulten Riedböcken des Krüger National Parks und bei einigen Riedböcken des Umfolozi Reservates (Natal) entwickelt. Sie erscheinen weniger deutlich bei Riedböcken von Ost- und Westtransvaal und einigen von Umfolozi

- sowie denen im Kyle Dam Reservat (Rhodesien) ausgebildet zu sein. Bei den Riedböcken des KNP und bei einigen aus Umfolozi sind die „Unterohrdrüsen“ als deutliche, schwarze, spärlich oder kurz behaarte, oft nackte Hautflecken unterhalb der Ohrmuschel ausgebildet. Bei Riedböcken vom Kyle Dam sowie einigen aus Umfolozi und Transvaal ist dieser Fleck nicht so deutlich sichtbar, sondern mehr oder weniger dicht mit kurzen Haaren besetzt. Gelegentlich schimmert nur im Zentrum dunkle Haut durch. Histologisch handelt es sich bei diesen Drüsen um Ansammlungen von einzelnen, unverzweigten, stark vergrößerten Haarbalgdrüsen (*Gll. sebaceae*), die nach dem holokrinen Typus sezernieren.
2. Die immer paarigen Inguinaldrüsen von *R. arundinum* des Krüger National Parkes sind blind endende, tütenförmige Taschen. Sie sind nur spärlich behaart, laufen nach unten spitz zu und münden trichterförmig nach außen. Ebenso wie die „Unterohrdrüsen“ stellen die Inguinaldrüsen stark vergrößerte, holokrine Haarbalgdrüsen dar, deren Sekret scharf riecht und deutlich sichtbar ist.
 3. Sowohl die „Unterohrdrüsen“ als auch die Inguinaldrüsen von *Redunca arundinum* scheinen im Sozialverhalten dieser Tiere von Bedeutung zu sein:
 - a. Sie stehen im Dienste der Territoriumsmarkierung
 - b. Sie vermitteln den Kontakt innerhalb der Paare und Familien.
 Eine Bedeutung dieser Drüsen für den direkten Kontakt zwischen ♂ und ♀ bei Paarungsspiel oder -nachspiel konnte nicht beobachtet werden.

References

- ANSELL, W. F. H. (1968): Preliminary identification manual for African mammals. Smithsonian Institution, Washington, D. C.
- BACKHAUS, W. (1959): Beobachtungen über das Freileben von Lelwel-Kuhantilopen *Alcelaphus buselaphus Lelwel* Heuglin (1863) und Gelegenheitsbeobachtungen an Sennar-Pferdeantilopen (*Hippotragus equinus bakeri* Heuglin 1863). Z. Säugetierkunde 24, 1—34.
- BRINKMANN, A. (1911): Die Hautdrüsen der Säugetiere (Bau- und Sekretionsverhältnisse). Ergebn. Anat. Entw. 20, 1173—1231.
- BUCHER, O. (1965): Histologie und mikroskopische Anatomie des Menschen. Hans Huber, Bern-Stuttgart.
- BUECHNER, H. K.; SCHLOETH, R. (1965): Ceremonial mating behaviour in Uganda Kob (*Adenota Kob thomasi*, Neumann). Z. Tierpsych. 22, 121—182.
- CLARA, M. (1929): Neue Untersuchungen zur Frage der Teilung bei den Talgdrüsen. Zugleich ein Beitrag zur Frage des „Stichotropismus“ in der Formbildung. Z. mikr.-anat.-Forsch. 18, 487—519.
- DIETRICH, L. (1965): Absetzen von Voraugensekret an den Hörnern von Artgenossen bei Gazellen und Dikdik. Säugetierkd. Mitt. 13, 147 ff.
- DOLLMANN, J. G. (1931): Development of auricular “glandular” patches in the Waterbucks. Proc. Linnean Soc. London 144, 86—87.
- MC. EWAN JENKINSON, D. (1972): The skin structure of British deer. Res. vet. Sci. 13, 70—73.
- HALTENORTH, T. (1963): Klassifikation der Säugetiere. Artiodactyla. Handbuch der Zoologie 8, 1—167.
- HEDIGER, H. (1949): Säugetierterritorien und ihre Markierungen. Bijdr. tot de Dierkde. 28, 171—184.
- HEYDEN, K. (1967): Studien zur Systematik von Cephalophinae BROOK (1876), Reduncini SIMPSON (1945) und Peleini SOKOLOV (1953) (Antilopinae BAIRD, 1857). Dissertation Universität Kiel.
- HOFMANN, R. R. (1972): Zur funktionellen Morphologie des Subauricularorgans des ostafrikanischen Bergriedbocks, *Redunca fulvorufula chanleri* (Rothschild, 1895), Tierärztl. Wschr. 85./24, 470—483.
- HORSTMANN, E. (1957): Die Haut. Handbuch der mikroskopischen Anatomie des Menschen, Ergänzung zu Bd. III/1. Springer Verlag, Berlin — Göttingen — Heidelberg.
- JUNGIUS, H. (1970): Studies on the Breeding Biology of the Reedbuck (*Redunca arundinum* Boddaert, 1785) in the Krüger National Park. Z. Säugetierkunde 35, 129—146.
- (1971a): The Biology and Behaviour of the Reedbuck (*Redunca arundinum* Boddaert, 1785) in the Kruger National Park. Mammalia depicta, Paul Parey, Hamburg — Berlin.
- (1971b): Food and feeding habits of the Reedbuck (*Redunca arundinum* Boddaert, 1785) in the Kruger National Park. Koedoe 14 (in press).
- KRIEG H. (1936): Das Reh in biologischer Betrachtung. Neumann — Neudamm.
- KURT, F. (1968): Das Sozialverhalten des Rehes. Mammalia depicta, Hamburg u. Berlin: Parey.
- LOBITZ, W. C. jr. (1957): The structure and function of the sebaceous glands. Arch. Dermat. (Chikago) 76, 162—171.

- MATOLTSY, A. G.; HUZSAR, TH. (1972): Keratinization of the reptilian epidermis: An ultrastructural study of the turtle skin. *J. Ultrastructure Research* **38**, 87—101.
- MONTAGNA, W. (1952): The cytology of mammalian epidermis and sebaceous glands. *Rev. Cytology* **1**, 265—304.
- (1962): The structure and function of skin. Academic Press, London – New York.
- MONTAGNA, W.; KENYON, P.; HAMILTON (1949): Growth potentials and mitotic division in sebaceous glands of the rabbit. *Anat. Rec.* **103**, 365—380.
- MONTAGNA, W.; NOBACK, C. R. (1946): The histology of the preputial gland of the rat. *Anat. Rec.* **96**, 41—54.
- NASR, A. N. (1965): Histochemical study of lipids in human sebaceous glands. *Cytochem.* **13**, 498—502.
- NEUBERT, K. (1930): Der Aufbau und die Entwicklung des menschlichen Talgorganes. *Z. Anat.* **92**, 565—621.
- OBOUSSIER, H. (1970): Beiträge zur Kenntnis der Pelea (*Pelea capreolus*, Bovidae, Mammalia), ein Vergleich mit etwa gleichgroßen Bovinae (*Redunca fulvorufula*, *Gazella thomsoni*, *Antidorcas marsupialis*). *Z. Säugetierkunde* **33**, 342—353.
- PIENAAR, U. DE V. (1963): The large mammals of the Kruger National Park — their distribution and present day status. *Koedoe* **6**, 1—38.
- RAHM, U. (1960): Territoriumsmarkierungen mit der Voraugendrüse beim Maxwell-Ducker (*Philantomba maxwelli*). *Säugetierkundl. Mitt.* **8**, 140.
- RICHTER, J. (1971): Untersuchungen an Antorbitaldrüsen von *Madoqua* (Bovidae, Mammalia). *Z. Säugetierkunde* **36**, 334—342.
- SCHAFFER, J. (1940): Die Hautdrüsen der Säugetiere. Urban und Schwarzenberg, Berlin – Wien.
- VON SCHUMACHER, S. (1943): Die Duftorgane (Hautdrüsenorgane) unseres Haarwildes. *Z. Jagdkunde* **5**.
- SIMPSON, W. L.; CRAMER, W. (1943): Fluorescence studies in skin. I. Histological localization of 20-methylcholanthrene in mouse skin after a single application. *Cancer Res.* **3**, 262—269.
- (1945): Fluorescence studies in skin. II. Mouse skin after single and multiple application of 20-methylcholanthrene. *Cancer Res.* **5**, 449—463.
- STARCK, D.; SCHNEIDER, R. (1971): Zur Kenntnis insbesondere der Hautdrüsen von *Pelea capreolus* (Forster, 1970) (Artiodactyla, Bovidae, Antilopinae, Peleini). *Z. Säugetierkunde* **36**, 321—333.
- WALTER, F. (1968): Das Verhalten der Gazellen. Neue Brehm Bücherei, Vol. 373, Wittenberg.
- WIENKER, H. G. (1968): Elektronenmikroskopische Untersuchungen an Talgdrüsen der Rückenhaut der Hauskatze. *Z. mikr.-anat. Forsch.* **78**, 211—234.
- ZIEGLER-SIMON, J. (1957): Beobachtungen am Rüsseldickdick (*Rhynchotragus kirki* [Gthr.]). *Der Zool. Garten (N. F.)*, **23**, (1—3), Leipzig.

Authors' address: Dr. C.-P. CLAUSSEN, Institut für Pathologie der Medizinischen Akademie Lübeck, 24 Lübeck, Kronsfordter Allee 71–73; Dr. H. JUNGUS, World-wildlife Fund, CH-1110 Morges

Cytogenetic Differentiation, Geographic Distribution, and Domestication in Palearctic Sheep (*Ovis*)

By C. F. NADLER, K. V. KOROBITSINA, R. S. HOFFMANN and N. N. VORONTSOV

Receipt of Ms. 29. 6. 1972

Many authors have contributed to the taxonomy of Palearctic sheep of the mouflon-urial-arkhar/argali types (SEVERTSOV 1873a, b; LYDEKKER 1898, 1912, 1913; NASONOV 1911, 1923; TSALKIN 1951; SOKOLOV 1959; HEPTNER et al. 1961). The existing taxonomic systems were reviewed in detail by TSALKIN (1951); Table 1 summarizes the number of species and subspecies recognized by different authors. Within

ZOBODAT - www.zobodat.at

Zoologisch-Botanische Datenbank/Zoological-Botanical Database

Digitale Literatur/Digital Literature

Zeitschrift/Journal: [Mammalian Biology \(früher Zeitschrift für Säugetierkunde\)](#)

Jahr/Year: 1972

Band/Volume: [38](#)

Autor(en)/Author(s): Claussen Claus-Peter, Jungius Hartmut

Artikel/Article: [On the Topography and Structure of the so-called Glandulär Subauricular Patch and the Inguinal Gland in the Reedbuck \(*Redunca arundinum*\) 97-109](#)