

Z. Säugetierkunde 54 (1989) 193–204
© 1989 Verlag Paul Parey, Hamburg und Berlin
ISSN 0044-3468

Developmental evidence for dental homologies in the monotreme *Ornithorhynchus* and its systematic implications

By W. P. LUCKETT and U. ZELLER

Abteilung Morphologie, Zentrum Anatomie der Universität Göttingen

Receipt of Ms. 27. 1. 1988

Abstract

Investigated the early development of the anterior cheek teeth in the platypus, *Ornithorhynchus anatinus* (order Monotremata), in order to assess its suggested similarities with the dental replacement pattern in marsupials. Histological serial sections of the head were examined for 12 ontogenetic stages, ranging from 8–10 mm embryos in incubated eggs to nestling, subadult, and adult animals. Results indicate that the small, abnormally developed, anterior cheek teeth (“dv”) in both jaws do not develop successor teeth, contrary to previous reports. We conclude that the developmental pattern of the platypus dentition is completely different from that of marsupials, and that there is no evidence from dental ontogeny to support the union of monotremes and marsupials in a higher taxon Marsupionta, contrary to an earlier suggestion by KÜHNE (1973, 1977).

Introduction

The discovery of fossil dental and skeletal remains of the monotreme family Ornithorhynchidae in middle Miocene deposits of Australia (WOODBURNE and TEDFORD 1975; ARCHER et al. 1978; LESTER and ARCHER 1986) has renewed interest in the question of the phylogenetic relationships of extant monotremes to other mammals. Partly because of the retention of numerous primitive mammalian and reptile-like features in their skeleton and soft anatomy, the extant monotremes *Ornithorhynchus*, *Tachyglossus* and *Zaglossus* have long been separated from other extant mammals as the subclass Prototheria (GILL 1872; GREGORY 1910; SIMPSON 1945; HOPSON 1970; MCKENNA 1975). In addition, most students of fossil and living mammals have also acknowledged a close relationship between Metatheria (marsupials) and Eutheria (placentals) and unite them in the subclass Theria.

A notable exception to this hypothesis of a prototherian-therian dichotomy was the proposal by GREGORY (1947) that monotremes were derived from early Australasian marsupials, and that Monotremata and Marsupialia therefore should be classified together in a new subclass Marsupionta. Among the shared cranioskeletal, reproductive and soft anatomical features cited by GREGORY to support this hypothesis was the presence of only a single deciduous premolar in each jaw of the platypus *Ornithorhynchus* and in marsupials. “There is evidence of one milk tooth in each jaw, this being in the premolar region and recalling the conditions in marsupials” (GREGORY 1947, p. 16). Further corroboration for GREGORY’s (1947) marsupiontan hypothesis was provided by KÜHNE (1973, 1977, 1987) in his cladistic analysis of dental replacement patterns in the platypus and other extant mammals. He claimed that marsupials and *Ornithorhynchus* are synapomorphic in exhibiting replacement at only a single postcanine tooth position, followed by four molars, in contrast to the plesiomorphic eutherian pattern of replacing three or four premolars.

KÜHNE’s (1973, 1977) arguments were founded on his reinterpretation of the histological study by GREEN (1937) on tooth development in a series of platypus nestlings. GREEN (1937) reported that a small abnormal deciduous premolar (“dv”) occurs in both jaws in specimens of 56–170 mm dorsal contour length (DCL). In addition, he claimed that in the lower jaw there was an “aborted tooth rudiment” for a successor of “dv” in some

specimens between 122–250 mm DCL. None of these rudimentary successor teeth was illustrated photographically, although GREEN (1937) included them in his schematic diagram of the idealized dentition of *Ornithorhynchus*. This diagram was reproduced by KÜHNE (1973, 1977) as evidence of tooth replacement for a single deciduous premolar in the platypus.

The marsupiontan hypothesis of GREGORY (1947) and KÜHNE (1973) has not been supported by comparative or cladistic analyses of numerous developmental, reproductive and cranioskeletal features in the three major groups of mammals (KUHN 1971; LUCKETT 1977; STARCK 1978; MARSHALL 1979; KUHN and ZELLER 1987; ZELLER 1987); instead, these analyses have provided strong corroboration for the traditional view of prototherian-therian dichotomy during mammalian phylogeny. Although several authors (PARRINGTON 1974; GRIFFITHS 1978; STARCK 1978; THENIUS 1979; MARSHALL 1979; AX 1984) have questioned KÜHNE's interpretation of tooth homologies in *Ornithorhynchus*, none has falsified his hypothesis by directly examining aspects of dental development in the platypus.

Recently, we have investigated various aspects of cranial (KUHN and ZELLER 1987; ZELLER 1987, in press, in prep.) and dental development (LUCKETT and ZELLER in prep.) in an extensive series of embryonic and nestling *Ornithorhynchus anatinus*, in order to clarify aspects of cranial and dental homologies and character state polarities among the major mammalian subgroups. In the present study, we limit ourselves to observations that relate to the suggested identification of a single deciduous and successor premolar in each jaw of the platypus, and to the systematic conclusions that KÜHNE (1973, 1977) has drawn from his postulated tooth homologies in this animal. We shall try to answer three interrelated questions in our ontogenetic analysis.

1. What is the evidence for identifying four molars and a single premolar in each jaw quadrant of *Ornithorhynchus*?
2. Is there distinct evidence for tooth replacement of a deciduous premolar?
3. Is the pattern of dental homologies and replacement synapomorphic for *Ornithorhynchus* and marsupials?

Material and methods

The 12 ontogenetic stages examined during this study ranged from 8–10 mm GL embryos in unhatched eggs to a series of nestling, subadult and adult stages (Table 1). Eight specimens were obtained from the collection of the late Professor J. P. HILL; this collection is currently maintained at the Hubrecht Laboratory, Utrecht, the Netherlands. Additional specimens were acquired from the American Museum of Natural History, New York, New York; National Museum of Natural

Table 1. Ontogenetic stages of *Ornithorhynchus anatinus* studied

Specimen	Specimen Number	Stain
8 mm GL Embryo	M 37 (Hub. Lab.)	H & E
9 mm GL Embryo	M 38 (Hub. Lab.)	H & E
9 mm GL Embryo*	MO 7 (Hub. Lab.)	Alcianblue
10 mm GL Embryo	M 42 (Hub. Lab.)	H & E
16.75 mm GL Newly-hatched	M 44 (Hub. Lab.)	H & E
(28 mm DCL)		
56 mm DCL Nestling	M 45 (Hub. Lab.)	H & E
74 mm DCL Nestling*	AMNH 201969	Azan
122 mm DCL Nestling*	MO 38 (Hub. Lab.)	Azan
180 mm DCL Nestling*	MO 39 (Hub. Lab.)	Azan
333 mm DCL Nestling*	USNM 221112	Azan
55.5 mm HL Nestling*	AMNH 201312	Azan
400 mm Total length Adult*	Coll. Dr. W. Hecker	Azan; H & E

History, Washington, D. C.; and from the Collection of Dr. W. HECKER, München. The heads of five of the embryonic and early nestling stages were sectioned previously, and some of these were studied by GREEN (1937). The preserved heads of the remaining seven specimens, marked by an asterisk in Table 1, were embedded in paraffin or celloidin and sectioned serially at 10–80 µm at the Abteilung Morphologie of the Zentrum Anatomie, Universität Göttingen (KUHN and ZELLER 1987; ZELLER 1987, in press, in prep.). Sections were stained with either Hematoxylin and Eosin (H and E) or Azan. Because of the unusual shape of the head and tail of posthatching *Ornithorhynchus*, we have adopted the “dorsal contour line” (DCL) measurement of WILSON and HILL (1907) and GREEN (1937) for our specimens. This measurement is taken along the dorsal curvature of the body, from the tip of the snout to the tip of the tail. Measurements of the embryonic and newly-hatched specimens in the HILL collection are documented according to their greatest length (GL). Serial sections were examined for each jaw quadrant, in order to record the developmental state of all tooth germs or thickenings of the dental lamina.

Results

Disagreement exists concerning the premolar or molar homologies of some of the transitory cheek teeth in *Ornithorhynchus*; therefore, we follow WILSON and HILL (1907) and GREEN (1937) in adopting the designation “dv”, “w”, “x”, “y” and “z” for the five cheek teeth that appear mesiodistally during posthatching life in each jaw quadrant of the platypus. The ontogeny of each of these teeth will be described in detail elsewhere (LUCKETT and ZELLER in prep.). In the present study we focus only on the development of the most anterior (= mesial) of these cheek teeth.

The bilateral dental laminae are evident as thickenings of the oral epithelium in the upper jaws of 8–9 mm platypus embryos, before the onset of ossification in the future praemaxillary, maxillary or dentary bones. Dental laminae are also present, although less differentiated, in the lower jaw. In the 10 mm embryo, there is a distinct bud-like thickening of the dental lamina at the level of the rostral extent of the early maxillary ossification, and a more elongate bud-like thickening of the lamina lies at the distal extent of the Os maxillare (Table 2). This latter bud-like swelling is overlain by the distal half of the developing eye. The lower lamina also exhibits two comparable thickenings, although the distal swelling is shallower, but wider, than that of the upper lamina.

In a newly-hatched platypus (16.75 mm GL; 28 mm DCL), prominent swellings also occur near the distal end of the dental lamina in both jaws. The elongate bud of the upper jaw is present just in front of the anterior margin of the small eye. The comparable thickening in the lower jaw is wider buccolingually, and it is asymmetrically indented on its inferior surface by the underlying mesenchyme to form an early cap stage (Fig. 1). The epithelium of this tooth germ is in broad communication with the overlying oral epithelium, so that an elongate dental lamina strand is not evident between the two epithelia. By comparison with later stages, as well as by observing its relationships to the developing eye and other cranial landmarks, this developing tooth germ is homologous with “dv” of later stages in both jaws, and to the distal bud-like swellings of the dental laminae in the 10 mm embryo. In this newly-hatched stage, the dental lamina extends slightly distal to “dv” in both jaws, but it does not yet form a distinct bud distal to this tooth germ.

In the next available stage, a nestling of 56 mm DCL, “dv” is considerably advanced developmentally in both jaws. Upper “dv” is in the bell stage and has a thin layer of dentin differentiated over its apex (Fig. 2). This small tooth is clearly abnormal in several respects. It remains in broad continuity with the oral epithelium and projects only slightly into the underlying mesenchyme. The inner enamel epithelium adjacent to the thin dental cap is overlain by a zone of slightly loosened epithelial cells, but the latter does not form a distinct stratum of stellate reticulum, nor is the outer enamel epithelial layer of the tooth germ clearly delimited from the overlying oral epithelium (Fig. 2). The comparable tooth in the lower jaw is less mature, and shows only a very thin layer of early predentin.

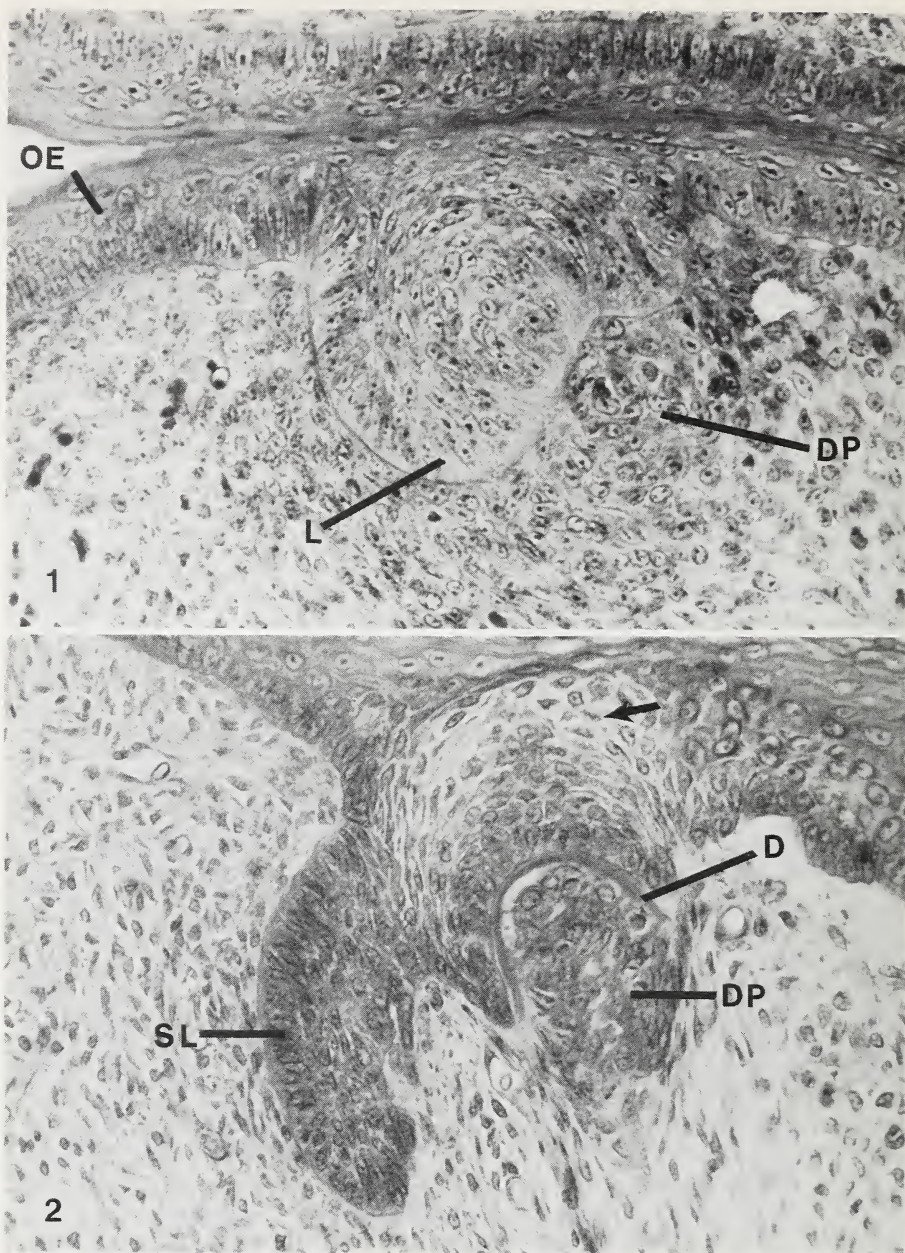


Fig. 1. *Ornithorhynchus anatinus* 28 mm DCL newly-hatched young. Transverse section through lower jaw at the level of the thickened early cap stage for "dv". Note the broad attachment of the tooth germ to the overlying oral epithelium (OE), and the asymmetry of the cap stage, with a smaller, darkly-stained buccal portion (at right), and a larger, inferiorly-projecting lingual portion (L). Early mesenchymal condensation is evident in the developing dental papilla (DP). ($\times 400$)

Fig. 2. *Ornithorhynchus anatinus* 56 mm DCL nestling. Transverse section through bell stage upper "dv", showing broad attachment to the oral epithelium, and early dentin (or predentin) cap (D) overlying the dental papilla (DP). Note the slight loosening of cells (arrow) marking the site of the potential stellate reticulum, and the slightly curved lingual "successional" lamina (SL), continuous with the oral epithelium and the outer enamel epithelium of the abnormal "dv". ($\times 400$)

A ridge-like successional lamina lies at the lingual side of the abnormal “dv”, and it projects deeper into the jaw stroma than does the buccal “dv”. The lingual successional lamina is continuous with the poorly-defined outer enamel epithelium of “dv” and with the oral epithelium (Fig. 2). Although the successional lamina appears to be slightly swollen, it is comparable in thickness to, and continuous with, the primary dental lamina that extends mesial to “dv”.

In contrast to the abnormal appearance of the small “dv” in the upper jaw, the larger tooth developing distal to this (tooth “w”) appears to be a relatively normal late bell stage, with moderately developed stellate reticulum, no odontoblasts or dentin, and no evidence for a lingual “successional” lamina (see Table 2). This tooth has undergone considerable development since the 28 mm DCL newly-hatched stage, where it was represented only by a short extent of the dental lamina. A similar tooth “w” also occurs in the lower jaw of the 56 mm DCL nestling.

In a later nestling of 74 mm DCL, “dv” is represented in both jaws by a relatively small, abnormal, irregular dental knot, in which scattered stromal cells and odontoblasts are entrapped (Fig. 3). As in the previous stage, the inner enamel epithelium is adherent to the basal surface of the oral epithelium, and a loosening of cells within the adjacent oral epithelium represents an abortive attempt at formation of stellate reticulum. The inner enamel epithelium does not differentiate into ameloblasts, and there is no formation of enamel in the abnormal “dv” of this or later stages. The lingual successional lamina ridge retains the same relative size and relationships as in the previous stage, in contrast to the further differentiation of the abnormal dental knot. The successional lamina is continuous distally with the primary dental lamina between “dv” and “w”.

The tiny, abnormal dental knot of “dv” has become more detached or delimited from the oral epithelium of both jaws in a 122 mm DCL nestling, and its lingual successional lamina is now relatively thin and folded, and it shows early evidence of fragmentation

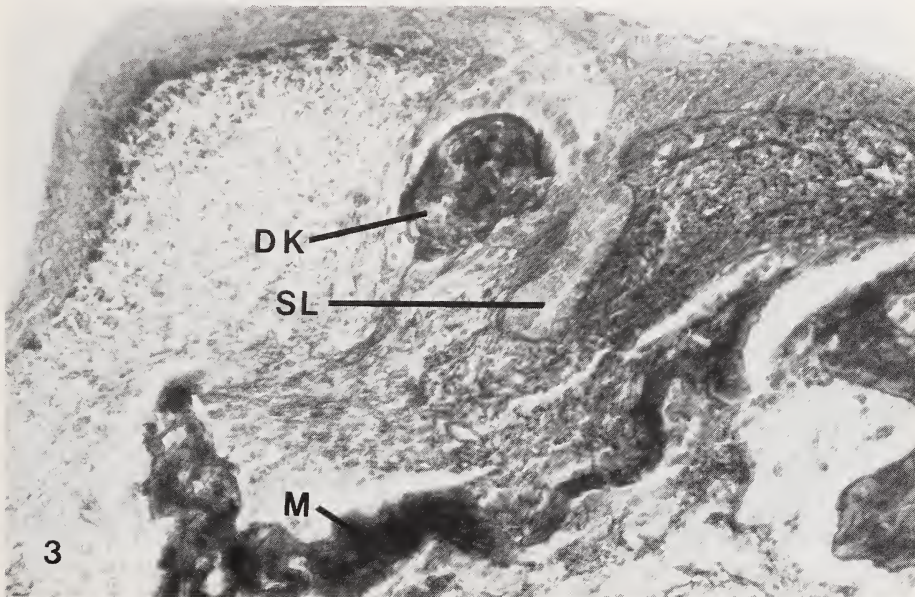


Fig. 3. *Ornithorhynchus anatinus* 74 mm DCL nestling. Transverse section through upper jaw with “dv” represented by an irregular dental knot (DK), closely adherent to the adjacent oral epithelium. The lingual “successional” lamina (SL) has not increased in thickness since the previous stage. Note the underlying maxillary bone trabeculae (M), partly detached from the adjacent mesenchyme. ($\times 256$)

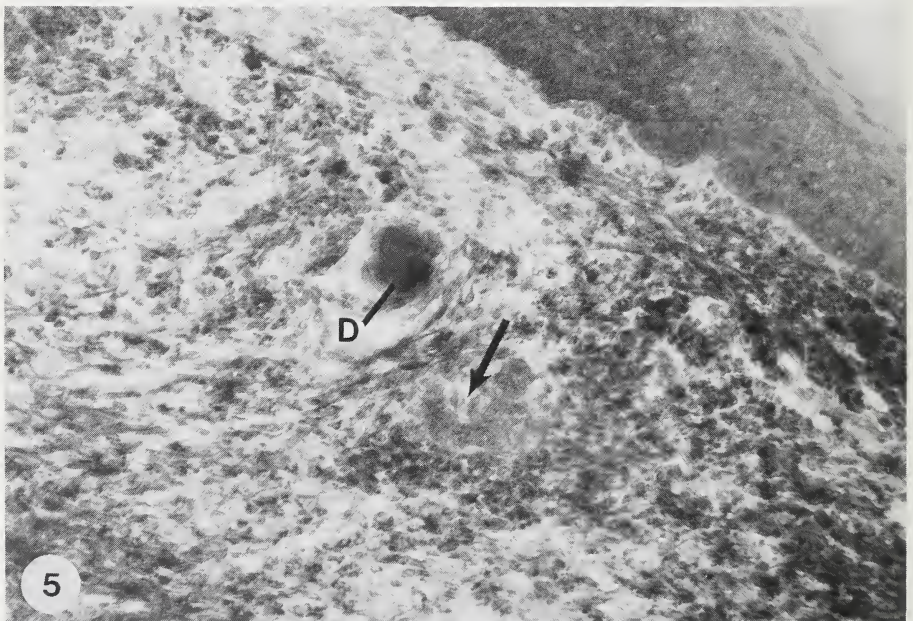
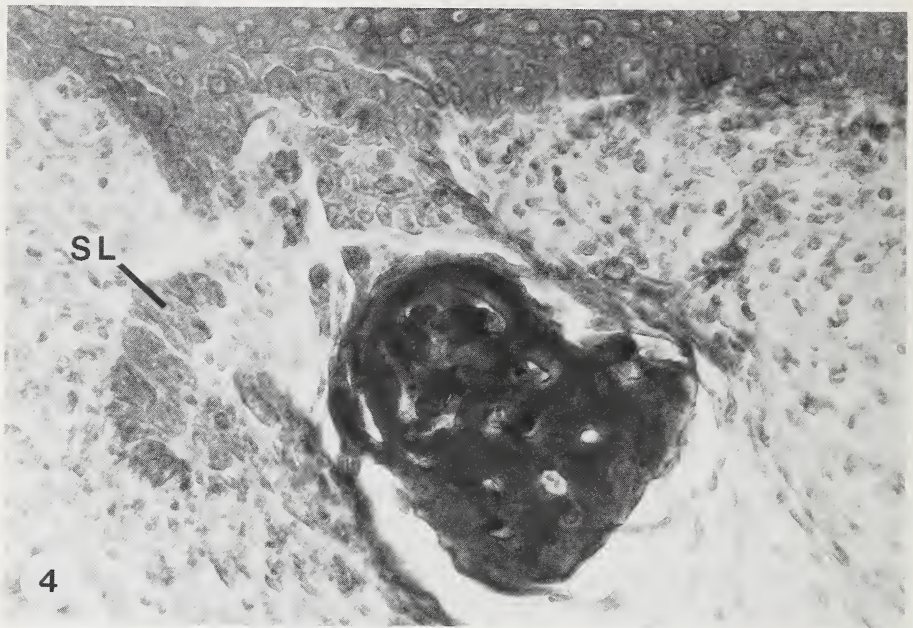


Fig. 4. *Ornithorhynchus anatinus* 122 mm DCL nestling. Transverse section through upper jaw, with irregular dental knot of "dv" beginning to become detached from the oral epithelium. Note the folded and early fragmented nature of the lingual "successional" lamina (SL). ($\times 400$)

Fig. 5. *Ornithorhynchus anatinus* 180 mm DCL nestling. Transverse section through lower jaw, with tiny dental fragment (D) representing the last remnant of abnormal "dv". An isolated, folded remnant of the lingual "successional" lamina is still evident (arrow). ($\times 256$)

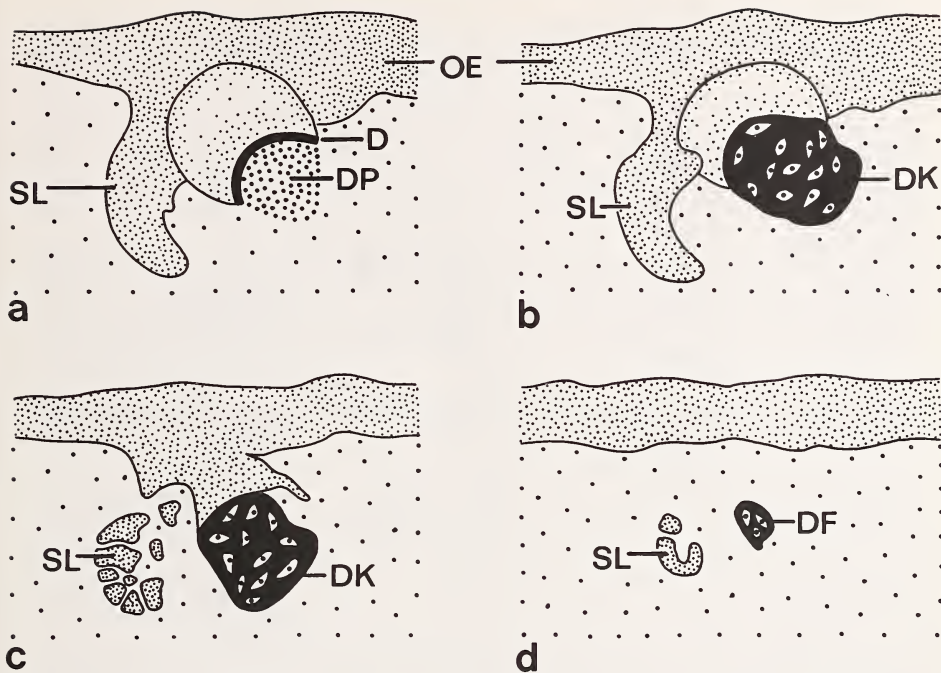


Fig. 6. Diagram of the ontogenetic relationships between the oral epithelium (OE), abnormal tooth "dv", and its successional lamina (SL) in *Ornithorhynchus anatinus* nestlings. Upper jaw of: a = 56 mm DCL; b = 74 mm DCL; c = 122 mm DCL nestlings. d = Lower jaw of 180 mm DCL nestling, with tiny, isolated dentinal remnant (DF) of "dv", as well as fragmented lingual successional lamina. D = Dentinal arc; DK = Dentinal knot; DP = Dental papilla

(Fig. 4), especially in the lower jaw. In the next available stage, a 180 mm DCL nestling, there is no trace of "dv" in the upper jaw, although a tiny isolated strand of dental lamina lying free within the stroma at the appropriate position may represent the last remnant of the successional lamina for "dv". In the lower jaw, a minute, irregular dentinal fragment lies free beneath the oral epithelium, and lingual to it is an isolated piece of flattened dental lamina (Fig. 5). These doubtlessly represent the last vestiges of "dv" and its successional lamina. No remnant of "dv" or its successor lamina was detected in a more mature 333 mm DCL nestling. A comparison of selected stages in the development and regression of "dv" is presented in Figure 6, and the major structural features of this tooth during ontogeny are compared to those of the more normal tooth "w" in Table 2.

Discussion

The observations of the present study provide no evidence to support the hypothesis that there is a rudimentary successor tooth for the small, abnormal deciduous premolar ("dv") of *Ornithorhynchus*. The earliest suggestion for "replacement" of a deciduous cheek tooth in the platypus was presented by WILSON and HILL (1907), based on their study of two juveniles. They described and illustrated a small, calcified deciduous tooth ("dv") with a slightly swollen lingual successional lamina, in both jaws of an 80 mm DCL nestling. In an older 250 mm stage, they found no trace of the abnormal "dv". However, they described "a small and rudimentary, but distinctly papillated, enamel-organ" (WILSON and HILL

Table 2. Developmental stages of "dv" and "w" in the upper jaw of *Ornithorhynchus*

Specimen	"dv"	Successor lamina of dv	"w"
10 mm GL Embryo	Distinct early bud-like thickening	—	—
16.75 mm GL (28 mm DCL) Newly-hatched	Distinct bud-like swelling	—	Dental lamina
56 mm DCL Nestling	Tiny, abnormal tooth; thin dental arc	Slightly swollen	Moderately large, late bell, no odontoblasts
74 mm DCL Nestling	Tiny, abnormal, irregular dental knot	Slightly swollen	Moderately large, late bell, early dentin; no distinct residual lamina
122 mm DCL Nestling	Tiny, abnormal, irregular dental knot	Flattened; early fragmentation	Large, late bell, moderately thick dentin; short residual lamina
180 mm DCL Nestling	No trace	Tiny dental lamina fragment	Moderate sized, thick den- tin, thin enamel; irregular residual lamina
333 mm DCL Nestling	No trace	No trace	Moderate sized, thick den- tin, moderately developed enamel; no distinct residual lamina

1907, p. 145) in the appropriate position in the upper jaw, and they considered this to be evidence of a true successor (tooth "v") for the missing "dv".

WILSON and HILL (1907, p. 148) suggested that the slightly enlarged lingual lamina of the younger stage was the "genuine representative" of the small "imperfectly formed" tooth "v" that they identified in the later 250 mm specimen. If this were true, then it would be expected that the lingual successional lamina of "dv" would exhibit intermediate stages of enlargement and differentiation in the platypus nestlings between 80–250 mm DCL described by GREEN (1937) and by us during the present investigation.

The nature of the successional lamina for "dv" in the 122 mm and 140 mm DCL nestlings was not described or illustrated by GREEN (1937), although he claimed to find evidence of an "aborted tooth rudiment" for successor "v" immediately in front of the abnormal lower "dv" in his 122 mm stage. Apparently, he detected no trace of a successor tooth "v" in the 140 mm stage, although "dv" was still represented by an abnormal dental knot. GREEN (1937) did not describe "dv" or "v" in his 200, 225, 250, and 295 mm DCL nestlings. Unfortunately, no photographs of the so-called rudimentary "successor" teeth were provided by WILSON and HILL or by GREEN. Despite this lack of documentation, GREEN (1937, p. 394) presented an "anachronistic diagram to show the ideal dentition of *Ornithorhynchus*", in which he illustrated the presence of both a deciduous and "replacing" tooth at the "v" position in both jaws.

In contrast, our study indicates that there is no relative increase in thickness of the lingual successional lamina of "dv" in specimens of 56, 74, 122, and 180 mm DCL, nor does this lamina differentiate into a distinct bud or cap stage. Indeed, the successional lamina of the 122 mm nestling is less differentiated than in the younger specimens, as evidenced by its relative thinness and early fragmentation; this is followed by greater fragmentation and loss of the successional lamina in the 180 mm nestling. It is possible that GREEN (1937) misinterpreted the folded and fragmented lingual lamina in his 122 mm DCL specimen as a distinct tooth rudiment for a successor "v". He also illustrated (GREEN 1937,

Fig. 42), but did not describe, a flattened and fragmented lingual successional lamina adjacent to a small dentinal knot remnant for "dv" in the lower jaw of a 170 mm DCL nestling, similar to the condition in our 180 mm specimen.

Teeth "dv" and "w" were considered to be premolars by WILSON and HILL (1907) and GREEN (1937), based in part on their small size and minimal degree of cusp differentiation, whereas the larger, multicuspidate, more distal teeth "x", "y", and "z" were identified as molars. However, tooth "w" was reinterpreted as a molar by KÜHNE (1973, 1977), because it shows no evidence of replacement. He emphasized that presence or absence of replacement, rather than size or shape, should be the main criterion for identifying premolars or molars. Although there is no evidence for development of a successor for tooth "dv", the pattern of early differentiation of the dentition in *Ornithorhynchus* is consistent with, but by no means proves, the hypothesis that this is a deciduous premolar, which is unreplaced during ontogeny. Comparison of the development of the dental lamina and early tooth buds with the state of differentiation of the nasal septum, Meckel's cartilage, jaw ossifications, and the eye in 8–10 mm platypus embryos with similar ontogenetic stages in marsupials and eutherians (LUCKETT 1988) suggests that the pattern of early dental development is homologous in the three major mammalian groups. Moreover, the two early tooth buds in the platypus upper jaw differentiate in association with the rostral and caudal extents of the early maxillary ossification, indentical with the developmental pattern for the deciduous canine and a posterior deciduous premolar (dP3 or dP4) in therians. Further development of the deciduous canine in the platypus is even more abnormal and more transitory than that of "dv" (GREEN 1937; LUCKETT and ZELLER in prep.).

HILL and DE BEER (1950) claimed that tooth "dv" is not serially homologous with mammalian deciduous teeth, because they believed that the former is not derived from the primary dental lamina, but instead differentiates directly from the oral epithelium that lies buccal to the dental lamina. However, our observations on earlier developmental stages clearly indicate that "dv" is derived from an early bud of the dental lamina, and that only secondarily does the abnormal tooth become displaced buccally. In later stages, "dv" in the platypus forms an abnormal dentinal knot, fails to develop enamel or a successor tooth, and is resorbed without erupting. This pattern of abnormal development and resorption of a deciduous premolar in *Ornithorhynchus* is convergently similar to the conditions for the abnormal first deciduous incisor in rodents and lagomorphs (LUCKETT 1985).

We agree with SIMPSON (1929) that it is difficult to resolve the premolar-molar homology of tooth "w" at present, due to the varying degree of abnormality for the entire dentition in the platypus. Tooth "w" is initiated somewhat later in ontogeny than is "dv", but the developmental gap between our 28 and 56 mm DCL nestlings makes it more difficult to assess the deciduous premolar or molar homologies of tooth "w" using embryological criteria. The possible identification of this tooth as a molar is provided by the nature of the epithelial lamina that differentiates at the lingual side of tooth "w". This lingual lamina is a poorly developed and transitory structure (Table 2) and is most comparable to the "residual lamina" of therian molars and successional antemolars, rather than to a "successional lamina". Such a residual lamina is not known to give rise to tooth germs in any extant mammal. Even though tooth "w" is more normal during its ontogeny than the small, abnormal "dv", its lingual lamina is more slender and less differentiated than that of "dv". These observations would be consistent with a hypothesis that the unreplaced tooth "w" is a molar rather than a premolar.

Nevertheless, the small size and nonmolariform nature of tooth "w" suggest that it is an unreplaced posterior deciduous premolar, rather than a molar. The known pattern of molar reduction and loss in mammals also supports this hypothesis. In fossil and extant mammals that have lost molars during phylogeny, such as some carnivores, macroscelids, muroid rodents, and platyrrhine primates, comparative and ontogenetic studies indicate that molars are lost at the distal rather than the mesial end of the tooth row (LECHE

1895; ZIEGLER 1971). The reduced size of the last lower molar (tooth "z") in *Ornithorhynchus*, coupled with its virtual loss in the upper jaw (GREEN 1937; LUCKETT and ZELLER, in prep.), is also consistent with these observations. We acknowledge, however, that our interpretation of premolar-molar homologies in *Ornithorhynchus* must remain tentative, due to the reduction and varying degree of abnormality of the entire dentition in the platypus, as well as to the complete lack of tooth germs, with the exception of the so-called egg tooth, in the echidna *Tachyglossus* (SEYDEL 1899).

Finally, the present investigation provides no evidence to support KÜHNE's (1973, 1977) hypothesis of monotreme-marsupial affinities, based on the supposed synapomorphy of homologous patterns of postcanine dental replacement. Our disagreement with KÜHNE occurs at two different levels. First, our ontogenetic study demonstrates the lack of differentiation of a distinct tooth germ on the lingual "successional" lamina of "dv", even though the supposed presence of a successor tooth at this locus was the central argument for KÜHNE's support of the marsupiontan hypothesis. As far as we can determine, KÜHNE examined no developmental stages of *Ornithorhynchus*, but relied instead on GREEN's (1937) poorly documented (and ultimately erroneous) report for the presence of such a successor tooth.

Secondly, we believe that the entire premise of KÜHNE's (1973, 1977) systematic argument for Marsupionta is poorly founded. Even if we had detected evidence for a single deciduous and successional premolar locus in *Ornithorhynchus*, this would still not indicate a probable synapomorphy shared with marsupials. Other mammals, such as caviomorph rodents, have the promolars reduced to a single locus in each jaw, with replacement of the deciduous premolar occurring in most cases (LUCKETT 1985). However, if a successor tooth for "dv" did develop in *Ornithorhynchus*, this would not constitute a synapomorphy shared with caviomorphs. If only a single premolar locus is present (as suggested by KÜHNE for the platypus), then only a single premolar locus could be replaced. On the other hand, marsupials are unique (= autapomorphous) among mammals in replacing only the last of the three premolar loci that occur in each jaw quadrant (KÜKENTHAL 1891).

KÜHNE (1973) appears to have been overly optimistic in his analysis of marsupiontan affinities when he claimed (p. 61) that "if only one synapomorphy is found and recognized as such, and generally acknowledged, the problem is solved". HENNIG (1966) emphasized that there are no simple and absolutely dependable criteria for distinguishing among synapomorphy, convergence, or parallelism, and that hypotheses of synapomorphy must therefore be continually tested and rechecked. Although KÜHNE's single dental synapomorphy for Marsupionta has not been "generally acknowledged" or accepted by most systematists, we share his concern (KÜHNE 1987) that this suggested synapomorphy has been dismissed by them as convergence, without any real evidence, other than by an appeal to parsimony. As shown in the present study, developmental evidence for a successor premolar in *Ornithorhynchus* is lacking; therefore, we falsify KÜHNE's hypothesis that a dental replacement synapomorphy exists between monotremes and marsupials. In conclusion, no corroboration of a special phylogenetic relationship between monotremes and marsupials is provided by our study of dental development and homologies in *Ornithorhynchus*.

Acknowledgements

The authors acknowledge the use of material of the Embryological Collection of the Hubrecht Laboratory, Netherlands Institute for Developmental Biology, Utrecht, The Netherlands, viz., the following specimens: *Ornithorhynchus anatinus* M37, M38, MO7, M42, M44, M45, MO38, and MO39. We wish to thank Dr. G. MÜSSER, American Museum of Natural History, New York, New York, Dr. R. W. THORINGTON, National Museum of Natural History, Washington, D.C., and Dr. A. LECHLEUTHNER, München, for the loan of *Ornithorhynchus* specimens (see Table 1). The expertise of Mrs. JUTTA ZELLER in the preparation of the new serial sections is gratefully acknowledged. The

authors thank Dr. NANCY HONG and Frau JOHANNA KÜHN for their help with the photographic work, and Mr. EGBERT VON BISCHOFFSHAUSEN for the drawing. We are indebted to Prof. DR. HANS-JÜRGEN KUHN for critically reading the manuscript. This study was supported in part by the Deutsche Forschungsgemeinschaft (Project Ku 131/7-1), and by a Senior U.S. Scientist Award from the Alexander von Humboldt Foundation, Bonn, to W. P. LUCKETT.

Zusammenfassung

Zur Ontogenese der Zähne von Ornithorhynchus und ihre Bedeutung für die systematische Stellung der Monotremen

Nach GREGORY (1947) und KÜHNE (1973) stimmen das Schnabeltier, *Ornithorhynchus anatinus* (Ordnung: Monotremata) und die Beuteltiere (Marsupialia) darin überein, daß in der Ontogenese nur ein Zahn gewechselt wird. Aufgrund dieser Übereinstimmung sollen die Monotremen mit den Marsupialien näher verwandt sein als mit den plazentalen Säugern (Eutheria); sie bilden nach GREGORY und KÜHNE gemeinsam das Taxon „Marsupionta“. Die bisherigen Angaben über die Ontogenese der Zähne von *Ornithorhynchus* sind lückenhaft. Zur Klärung der Fragen nach Vorkommen oder Fehlen eines Zahnwechsels und möglicher Übereinstimmung mit den Verhältnissen bei den Beuteltieren wurde die Ontogenese der Zähne von *Ornithorhynchus* anhand von 12 Schnittserien durch Köpfe von Embryonen (8–10 mm GL), Nestjungen sowie von einem subadulten und einem adulten Tier untersucht. Das Frontzahngebiß von *Ornithorhynchus* ist stark reduziert. Im Gegensatz zu älteren Angaben entsteht an dem kleinen, stark reduzierten, fünftletzten Zahnkeim „dv“, der bereits vor dem Durchbruch resorbiert wird, keine Ersatzzahnanlage. Die Zahnleiste lingual von „dv“ entwickelt sich in der Ontogenese nicht weiter, sondern zerfällt in einzelne Fragmente und wird, ebenso wie „dv“, restlos resorbiert. Auch keiner der nach distal folgenden Zähne „w“, „x“, „y“ oder „z“ wird gewechselt. Die Ontogenese der Zähne von *Ornithorhynchus* weist hinsichtlich des Zahnwechsels keinerlei Übereinstimmung mit derjenigen der Beuteltiere auf und gibt deshalb auch keine Hinweise auf eine nähere Verwandtschaft der Monotremen zu den Marsupialien. Auf der Grundlage der Zahnentwicklung läßt sich das Taxon „Marsupionta“ nicht begründen. Demgegenüber ist die systematische Einheit „Theria“ (Marsupialia und Eutheria) aufgrund zahlreicher Synapomorphien von Beuteltieren und plazentalen Säugern sicher begründet.

References

- ARCHER, M.; PLANE, M. D.; PLEDGE, N. S. (1978): Additional evidence for interpreting the Miocene *Obdurodon insignis* Woodburne and Tedford, 1975, to be a fossil platypus (Ornithorhynchidae: Monotremata) and a reconsideration of the status of *Ornithorhynchus agilis* De Vis, 1885. *Aust. Zool.* 20, 9–27.
- AX, P. (1984): Das phylogenetische System. Stuttgart, New York: G. Fischer.
- GILL, T. (1872): Arrangement of the families of mammals and synoptical table of the characters of the subdivisions of mammals. *Smithsonian Misc. Coll.* 11, 1–98.
- GREEN, H. L. H. (1937): The development and morphology of the teeth of *Ornithorhynchus*. *Phil. Trans. Roy. Soc. London, Series B* 228, 367–420.
- GREGORY, W. K. (1910): The orders of mammals. *Bull. Am. Mus. nat. Hist.* 27, 1–524.
- (1947): The monotremes and the palimpsest theory. *Bull. Am. Mus. nat. Hist.* 88, 1–52.
- GRIFFITHS, M. (1978): The biology of the monotremes. New York, San Francisco, London: Academic Press.
- HENNIG, W. (1966): *Phylogenetic systematics*. Urbana: University of Illinois Press.
- HILL, J. P.; DE BEER, G. R. (1950): Development of the Monotremata. Part VII. The development and structure of the egg-tooth and caruncle in marsupials. *Trans. Zool. Soc. Lond.* 26, 503–544.
- HOPSON, J. A. (1970): The classification of nontherian mammals. *J. Mammalogy* 51, 1–9.
- KÜHNE, W. G. (1973): The systematic position of monotremes reconsidered (Mammalia). *Z. Morph. Tiere* 75, 59–64.
- (1977): On the Marsupionta, a reply to Dr. Parrington. *J. nat. Hist.* 11, 225–228.
- (1987): Marsupionta contra Theria. In: *Deutsche Ges. Säugetierkunde*, 61. Hauptversammlung, Kurzfassungen der Vorträge u. Posteremonstr. Ed. by C. Schmidt. Hamburg, Berlin: Paul Parey, 26–27.
- KÜENTHAL, W. (1891): Das Gebiß von *Didelphys*. *Anat. Anz.* 6, 658–666.
- KUHN, H.-J. (1971): Die Entwicklung und Morphologie des Schädels von *Tachyglossus aculeatus*. *Abh. senckenb. naturforsch. Ges.* 528, 1–224.
- KUHN, H.-J.; ZELLER, U. (1987): The Cavum epiptericum in monotremes and therian mammals. In: *Morphogenesis of the mammalian skull*. Ed. by H.-J. Kuhn and U. Zeller. *Mammalia depicta*, (Beihefte Z. Säugetierkunde) Nr. 13, 51–70.

- LECHE, W. (1895): Zur Entwicklungsgeschichte des Zahnsystems der Säugetiere. Theil I, Ontogenie. *Bibliotheca Zoologica* 17, 1–160.
- LESTER, K. S.; ARCHER, M. (1986): A description of the molar enamel of a middle Miocene monotreme (*Obdurodon*, Ornithorhynchidae). *Anat. Embryol.* 174, 145–151.
- LUCKETT, W. P. (1977): Ontogeny of amniote fetal membranes and their application to phylogeny. In: Major patterns in vertebrate evolution. Ed. by M. K. Hecht, P. C. Goody and B. M. Hecht. New York: Plenum Press. pp. 439–516.
- (1985): Superordinal and intraordinal affinities of rodents: developmental evidence from the dentition and placentation. In: Evolutionary relationships among rodents. A multidisciplinary analysis. Ed. by W. P. Luckett and J.-L. Hartenberger. New York, London: Plenum Press. pp. 227–276.
- (1988): Early development and homology of the dental lamina and tooth buds in eutherian, metatherian, and prototherian mammals. *Anat. Rec.* 220, 60A.
- LUCKETT, W. P.; ZELLER, U.: Development of the teeth in *Ornithorhynchus*, and its implications to the phylogeny of mammals. (In prep.)
- MARSHALL, L. G. (1979): Evolution of metatherian and eutherian (mammalian) characters: a review based on cladistic methodology. *Zool. J. Linn. Soc.* 66, 369–410.
- MCKENNA, M. C. (1975): Toward a phylogenetic classification of the Mammalia. In: Phylogeny of the primates. A multidisciplinary approach. Ed. by W. P. Luckett and F. S. Szalay, New York, London: Plenum Press. pp. 21–46.
- PARRINGTON, F. R. (1974): The problem of the origin of the monotremes. *J. nat. Hist.* 8, 421–426.
- SEYDEL, O. (1899): Über Entwicklungsvorgänge an der Nasenhöhle und am Mundhöhlendache von *Echidna* nebst Beiträgen zur Morphologie des peripheren Geruchsorgans und des Gaumens der Wirbeltiere. *Semon. Zool. Forschungsreisen in Australien* 3, 2 (2), 445–532.
- SIMPSON, G. G. (1929): The dentition of *Ornithorhynchus* as evidence of its affinities. *Am. Mus. Novit.* 390, 1–15.
- (1945): The principles of classification and a classification of mammals. *Bull. Am. Mus. nat. Hist.* 85, 1–350.
- STARCK, D. (1978): Das evolutive Plateau Säugetier. *Sonderbd. naturwiss. Verein Hamburg* 3, 7–33.
- THENIUS, E. (1979): Die Evolution der Säugetiere. Stuttgart: G. Fischer.
- WILSON, J. T.; HILL, J. P. (1907): Observations on tooth-development in *Ornithorhynchus*. *Quart. J. Microscop. Sci.* 51, 137–165.
- WOODBURNE, M. O.; TEDFORD, R. H. (1975): The first Tertiary monotreme from Australia. *Am. Mus. Novit.* 2588, 1–11.
- ZELLER, U. (1987): Die Schädelentwicklung von *Ornithorhynchus* und die systematische Stellung der Monotremen. *Deutsche Ges. Säugetierkunde*, 61. Hauptversammlg., Kurzfassungen der Vorträge und Posterdemonstr. Ed. by C. Schmidt. Hamburg, Berlin: Paul Parey. pp. 55–56.
- (in press): The braincase of *Ornithorhynchus*. In: Fortschritte der Zoologie. Vol. 35. Ed. by H. Splechna, and H. Hilgers. Stuttgart, New York: G. Fischer.
- : Die Ontogenese und Morphologie des Schädels von *Ornithorhynchus anatinus* (In prep.)
- ZIEGLER, A. C. (1971): A theory of the evolution of therian dental formulas and replacement patterns. *Quart. Rev. Biol.* 46, 226–249.

Authors' addresses: Dr. W. PATRICK LUCKETT, Department of Anatomy, University of Puerto Rico School of Medicine, GPO Box 5067, San Juan, Puerto Rico 00936, USA; and Dr. ULRICH ZELLER, Abt. Morphologie, Zentrum Anatomie der Universität Göttingen, Kreuzberggring 36, D-3400 Göttingen, FRG

ZOBODAT - www.zobodat.at

Zoologisch-Botanische Datenbank/Zoological-Botanical Database

Digitale Literatur/Digital Literature

Zeitschrift/Journal: [Mammalian Biology \(früher Zeitschrift für Säugetierkunde\)](#)

Jahr/Year: 1989

Band/Volume: [54](#)

Autor(en)/Author(s): Zeller Ulrich, Luckett W. Patrick

Artikel/Article: [Developmental evidence for dental homologies in the monotreme Ornithorhynchus and its systematic implications 193-204](#)