



Rumen morphology and volatile fatty acid production in the Blue duiker (*Cephalophus monticola*) and the Red duiker (*Cephalophus natalensis*)

By ALIDA S. FAURIE and M. R. PERRIN

Department of Zoology and Entomology, University of Natal, Scottsville, South Africa

Receipt of Ms. 25. 09. 1991

Acceptance of Ms. 10. 09. 1994

Abstract

Blue duikers and red duikers have very similar rumen anatomy. In both species the rumen is a simple, plesiomorphic, sacculated S-shaped tube, while the ostia are large and the ruminal pillars weak. These specialisations facilitate rapid digesta passage. The rumens are densely papillated, and the fungiform papillae are highly vascular to aid absorption. Many of the adaptations are characteristic of concentrate selectors. Total concentrations of numeral fatty acids are lower in the red duiker than the blue duiker. Propionic and butyric acid concentrations are higher in the blue duiker than the red duiker while acetic acid concentration are greater in red duikers. Caecal concentrations of volatile fatty acids (especially acetic acid) are greater than those in the rumen of the blue duiker, but likely contribute less energy to metabolism because of the small size of the caecum relative to that of the rumen.

Introduction

Blue duikers (*Cephalophus monticola*) and red duikers (*Cephalophus natalensis*) are amongst the smallest antelope species, and are classified as concentrate selectors based on diet selection, and the morphology of the digestive tract, especially the rumen (HOFMANN 1973). Both species have a diet of mainly freshly fallen leaves, and to a lesser extent fallen fruit (FAURIE 1990; BOWLAND 1991). The aim of this study was to compare the morphology and histology of the rumen of the two closely related, sympatric, forest duikers and to correlate structure with function. Function was determined largely by quantifying volatile fatty acid (VFA) production in the rumen.

HOFMANN (1973, 1983) characterised the concentrate selectors as a group of bovids having certain morphological features in common, *i. e.*, a simple, small rumenoreticulum; rapid passage of food due to wide ostia; extensive rumen papillae providing a large absorptive area; a relatively large reticulum; a small omasum for transporting and straining food particles; relatively large salivary glands; a relatively short intestine, and with the caecum and colon forming a distal fermentation chamber.

LANGER (1974) has indicated that foregut fermenters probably evolved in regions where adequate quantities of low quality food were available, such as tropical forests. Small forest artiodactyls, of the family Tragulidae, have a 'primitive' rumen in the form of an S-shaped tube that reveals the ancestral arrangement of the foregut (HOFMANN 1968; LANGER 1974). Forest duikers and other small African antelope (Bovidae) possess a stomach with a similar anatomy (HOFMANN 1973) for rapid passage of food.

For small duikers, the most important source of energy is the volatile fatty acids (pri-

marily acetic, propionic and butyric), the major metabolizable end products of microbial anaerobic fermentation (KREULEN and HOPPE 1979; HUME and WARNER 1980), which represent 21–75% of digestible energy intake (VAN HOVEN and BOOMKER 1981; ROBBINS 1983). Recent research has estimated the bacterial and fungal numbers in ruminal and caecal contents of the blue duiker (DEHORITY and VARGA 1991).

Material and methods

Animals

Four red duikers (2 males (R1 and R3) and 2 females (R2 and R4)) and four blue duikers (2 males (B1 and B4) and 2 females (B2 and B3)) were used to examine rumen morphology and histology and to quantify rumen VFA concentrations. All the duikers were adult animals. With the exception of the one captive blue duiker, all the animals were shot in their natural habitats. The captive blue duiker (male B1) had been fed an experimental diet of Hunters horse cubes (14% protein, 10% fibre), fresh fruit (apples and carrots) and *ad lib.* water for three weeks prior to death. All four red duikers as well as blue duikers B1 (captive male) and B2 (female) were transported to a laboratory within 10 minutes to one hour after death. The remaining two blue duikers (B3 and B4) were frozen whole shortly after death and rumen fluid only was collected after the animals had been unfrozen.

Morphology

Stomachs (rumen, reticulum, omasum, and abomasum) were collected and preserved in four percent buffered formalin. A dissecting photomicroscope was used for gross morphological examinations. Compartments and structures of the red duiker and blue duiker stomachs were measured and photographed, while the papillae occupying various regions of the rumen were counted and measured to determine the surface area enlargement.

Histology

For histological examination, small portions of tissue were taken from the different stomach compartments within one hour after sacrifice. Tissues were fixed in Bouin's fixative for 12–18 hours, dehydrated in a series of alcohol concentrations, cleared in xylene and embedded in paraffin wax. Sections were cut on a microtome at 7 μ m, and stained with Ehrlich's haematoxylin and eosin. Photographs of histological sections (10 \times and 40 \times magnification) were taken through a Zeiss photomicroscope.

Physiology

Rumen pH was measured, body mass determined, and rumen fluid samples were taken to determine the concentrations of the individual VFAs. Fluid from the caecum of blue duiker B2 (female) was also collected and analysed for individual VFA concentrations.

In the laboratory, samples were left to equilibrate at room temperature (20°C). To 5 ml of the rumen fluid 1 ml of 25% metaphosphoric acid solution was added and allowed to stand for 10 minutes. The solution was centrifuged at 8000 RPM for 20 minutes, and in a high speed centrifuge at 18000 RPM for 20 minutes at 4°C. The supernatant was analysed on an HP 5970 A gas chromatograph with a flame ionisation detector and N₂ as the carrier gas. The chromatograph was equipped with a 2 \times 4 mm glass column, packed with 10% S-P 1200 + 1% H₃PO₄ on chromosorb W-AW 80/100 mesh.

Standard curves were constructed for acetic, propionic and butyric acids by injecting known amounts of standard solution, over the approximate range of 0–150 nmoles of acetic acid (and proportional amounts of the other two acids). The rumen fluid samples were injected into the chromatograph and the elution times compared with those of the standard (KELLOG 1969) to identify the VFA present, and its concentration.

Results

Morphology

Figure 1 shows the ruminant stomach of the blue duiker to be a blind-ending S-shaped tube. The rumen was divided into dorsal and ventral sacs by rumen pillars, the ventral sac being the larger. The ruminal pillars were simple wall duplications, only very slightly thickened but densely papillated, making them relatively inconspicuous. The bisected stomach (of the captive blue duiker) showed an evenly and very densely papillated rumen. The papillae were widespread, thereby enlarging the absorptive area of the rumen. The food retaining structures, the ruminal pillars and ostia, were very poorly developed, while the opening between the rumen and reticulum was very large. The coronary pillars were generally poorly developed while the dorsal one was absent. The rumeno-reticular opening and pillar were also covered with papillae. The ostium connecting the reticulum and omasum was relatively large, while the omasum was very small and had few laminae (6–8) with spatulate papillae.

In the captive blue duiker fed pellets, rumen fungiform papillae were short, broad (3×1 mm), and very densely packed (Fig. 2) while the whole rumen was covered by papillae of similar shape and density. Figure 3 shows that the rumen of a free ranging blue duiker fed on a natural diet possessed fewer papillae than that fed on a high protein, artificial diet. The foliate (vallate) papillae were thinner, longer and less regular in shape. The rumen papillae of the red duiker were very similar to the fungiform papillae of the free ranging blue duiker. The papillae approximated $5 \times 2 \times 2$ mm in size and the entire rumen was very evenly covered by papillae of similar size and shape. There were about 90–100 papillae/cm² which gives a surface enlargement in the order of 15–20×. On the rumeno-reticular pillar and the opening between the rumen and reticulum, the papillae were longer and more slender (Fig. 4). The

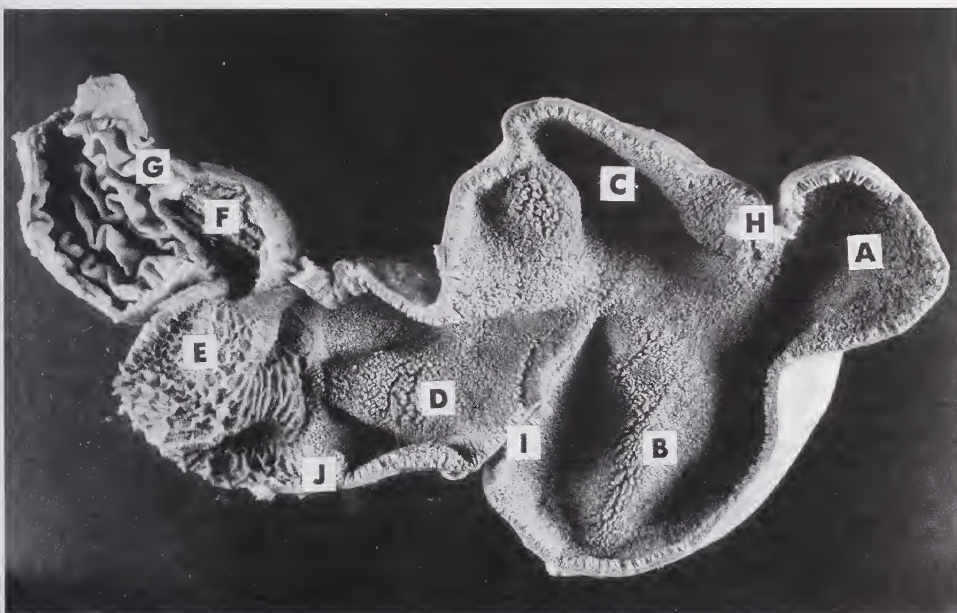


Fig. 1. Bisected stomach of captive blue duiker. A – ventral blindsac; B – saccus ventralis; C – dorsal blindsac; D – atrium ruminis (dorsal sac); E – reticulum; F – omasum; G – abomasum; H – caudal pillar; I – cranial pillar; J – rumeno-reticular fold.

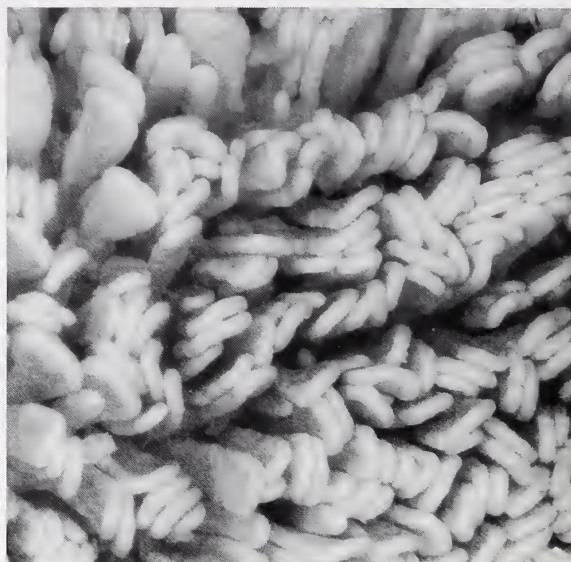

Fig. 2. Fungiform rumen papillae of the captive blue duiker fed a high protein/low fibre pelleted diet.

reticular mucosae of the red duiker and the blue duiker were very similar, and consisted of a honeycomb pattern with low bordering ridges. It was much more rigid and keratinized than that of the rumen and omasum. In the captive blue duiker, the cornified epithelial crests of the cells became very densely packed. The omasum in each species was small, and consisted of only six to eight leaflets, with spatulate papillae covering the entire epithelium.

Histology

The forestomach mucosa is the main medium of absorption from the stomach lumen into the vascular system (e.g. papillae in the rumen, and interpapillary mucosa of the omasal laminae and the reticulum) but it also serves a mechanical, protective function. Forestomach epithelium with an absorptive function is characterized by primary and secondary swelling of the epithelial cells, which are separated by a barrier layer of dense flattened cells. The papillae of the rumeno-reticulum consisted of epithelium, connective tissue and a central system of branched blood vessels. There was no histological difference between atrial papillae and those of the dorsal and ventral blindsacs of blue duikers and red duikers. The rumen epithelium comprised the stratum germinativum, stratum spinosum, stratum granulosum and the stratum corneum; the latter tissue was not highly cornified however, and consisted of a thin barrier layer with balloon cells (Fig. 5). Balloon cells are parakeratotic cells commonly found in concentrate feeders, and were clearly evident in both duiker species. Marginal arteries and venules (Fig. 5) were evident. Capillaries from the former were located within the papillae occultae. Basal epithelial cells between the papillae occultae established contact with the vascular system and venules characterized the epithelium of the absorptive papillae. In papillae with relatively thin epithelia, that consisted of only a few layers, the stratum spinosum was not very extensive. In the absorptive mucosa the nuclei of these cells were well defined in contrast to those in the protective mucosa.

The abomasum was connected to the omasum through the ostium omasoabomasicum. The abomasum was lined with spiral pillars of varying height. These pillars were formed

by mucosal duplications underlain by a vascular submucosa in both duiker species; the abomasum had 10 to 14 pillars lined with fundic glandular mucosa.

Physiology

Rumen pH, molar proportions of the individual VFAs, and the acetic:propionic acid ratios for each species are given in table 1. The pH values were very similar for both species, although that of the captive blue duiker was slightly lower. The molar proportions,

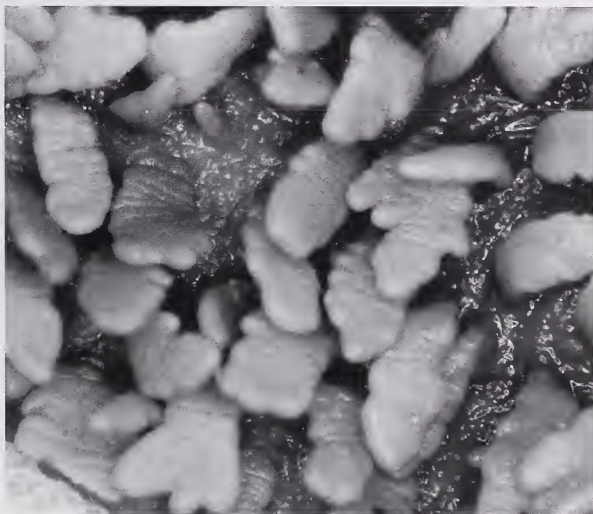


Fig. 3. Foliate (villate), ruminal papillae of a blue duiker that had been feeding on natural vegetation.



Fig. 4. Absorptive papillae on the rumeno-reticular pillar and ostium of a red duiker.

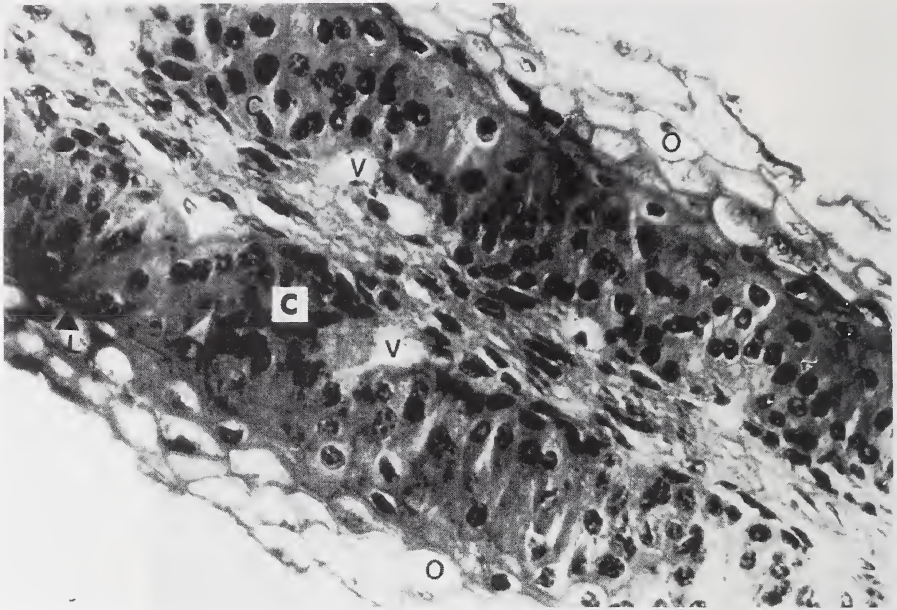


Fig. 5. Section of a ruminal papilla of a blue duiker. O – balloon cells; C – epithelial plug; L – barrier layer; V – venule.

Table 1. Relative volatile fatty acid (VFA) composition of the rumen fluid of blue duikers and red duikers.

Blue duikers	pH	Percentage VFA			A:P Ratio	Total (mM/l)
		Acetic (A)	Propionic (P)	Butyric		
B1 (captive)	5.9	52	32	16	1.6:1	60
B2	6.1	60	32	8	1.9:1	62
B3	–	64	28	8	2.3:1	–
B4	–	56	37	7	1.5:1	–
Mean	6.0	58	32	10	1.8:1	61
Red duikers						
R1	6.1	72	21	7	3.4:1	60
R2	6.0	74	20	6	3.7:1	70
R3	6.2	76	21	3	3.6:1	74
R4	6.2	74	23	3	3.2:1	74
Mean	6.1	75	21	5	3.6:1	70

and thus the acetic:propionic ratios were equivalent intraspecifically, but differences between species were evident. Sample sizes, however, were too small for reliable statistical analysis.

The (relative) composition of ruminal VFAs in red duikers and blue duikers were lower than but comparable to those of other small bovids (Tab. 2), particularly with species feeding on similar diets (*e.g.* suni, *Neotragus moschatus* and grey duiker, *Sylvicapra grim-*

Table 2. A comparison of the volatile fatty acid (VFA) composition of the rumen fluid of several small bovid species.

Species	Percentage VFA			A:P Ratio	Total	
	Acetic	Propionic	Butyric		(mM/l)	Ref.
Impala (<i>Aepycerus melampus</i>)	75	16	9	4.7:1	150	B
Grant's Gazelle (<i>Gazelle granti</i>)	78	17	5	4.6:1	141	A
Thomson's gazelle (<i>G. thomsoni</i>)	79	15	6	5.3:1	143	A
Grey duiker (<i>Sylvicapra grimmia</i>)	75	18	7	4.2:1	115	B
Harvey's duiker (<i>Cephalophus natalensis harveyi</i>)	77	18	5	4.3:1	144	B
Suni (<i>Neotragus moschatus</i>)	77	17	7	4.5:1	90	B
Dikdik (<i>Madoqua kirkii</i>)	72	20	8	3.6:1	109	B

References: A = HOPPE *et al.* (1977); B = HOPPE (1984).

Table 3. pH and volatile fatty acid composition of the abomasal and caecal fluid of the blue duiker.

	Abomasum (Captive)	Caecum (Wild)
pH	2.5	–
Total VFA (mM/l)	4	90
Acetic (%)	83	82
Propionic (%)	6	15
Butyric (%)	11	3
Acetic: Propionic ratio	13.8:1	5.5:1

mia). The low acetic:propionic ratio in the red duikers, was even more pronounced in the blue duikers (Tab. 1). In the captive blue duiker, acetic acid contributed only 52% of the VFAs with propionic and butyric acids accounting for the remainder.

Table 3 reports some data on the pH and VFA concentrations in the abomasum of the captive blue duiker, and the caecum of a wild blue duiker. The concentration of VFAs in the caecum was high.

Discussion

Morphology

It has been postulated that the structural components of the stomach that regulate food passage and intake, are so firmly established that they remain unaffected by dietary change, and, therefore, determine the limits of the adaptability of a species (HOFMANN 1973; VON ENGELHARDT 1981). Concentrate selectors are recognized as being less adaptable than grazers (HOPPE 1984). These parameters include the capacity of the rumen, the size of the ostia between the chambers, the type of contraction mechanism, and the anatomical structures (including pillars) that serve as a contracting mechanism to delay food passage. Blue duiker and red duiker have a simple stomach which facilitates a fast passage rate, and, rapid fermentation and absorption. This simple structure of the rumeno-reticulum, the poorly developed ruminal pillars, and the large ostium are characteristic of concentrate selectors (HOFMANN 1973).

The very poorly developed ruminal pillars and large ostia of the rumenoreticulum indicate a fast passage rate in the two duiker species. Passage rate in the two subject species approximates 18 to 24 hours (FAURIE 1990), similar to that of the suni, *Neotragus moschatus*, which has a passage rate of 12 to 22 hours (HOPPE and GWYNNE 1978). Parra (1978) and DEMMENT (1982) postulate that maximum rumen capacity and energy demands determine retention time. Thus, concentrate selectors with small rumens and high energy demands must have rapid passage rates.

LANGER (1974) points out that only in the Pecora does the proximal part of the hind-stomach help to form the omasum. The omasum delays digesta passage and is involved in the absorption of water, inorganic compounds, and VFA (LANGER 1974). The size of the omasum and the differentiation of the laminae differs considerably between the different feeding guilds. In concentrate selectors, the omasum is small and has very few laminae, indicating mainly a transport and strainer function. This is evident in the red duiker and blue duiker which have an average of six to eight primary laminae, and only in the case of the red duiker a few leaflets of the second order. In both species the laminae are densely studded with spatulate papillae. HOFMANN (1973) points out that this type of omasal lamina reflects the mechanical function of the omasum, as a strainer, and muscular suction pump.

In red duikers and blue duikers all areas in the rumen are papillated. There is some spatial variation in the size and density of ruminal papillae of free-living blue duiker and red duiker, *e.g.* smaller papillae occur on the rumen pillars than on the dorsal sac, but longer, more slender papillae occur near the rumeno-reticular pillar of the red duiker. The rumen papillae of Harvey's red duiker, *Cephalophus natalensis harveyi* and grey duiker, *Sylvicapra grimmia* exhibit similar local variation (HOFMANN 1973). The rumen papillae of the captive blue duiker, however, showed total uniformity, with no variation present.

Histology

Under changing feeding conditions, and a lowered pH, the barrier layer cells of rumen papillae change into flat balloon cells or parakeratotic swollen cells (HOUPPT 1970). These swollen cells are indicative of increased absorption and are usually accompanied by an extensive subepithelial vascular system. Evidence for a faster rate of solute absorption with increased vascularisation of papillae is given by DOBSON (1970). Extremely thin barrier layers are usually associated with animals feeding on rapidly fermentable food, *i.e.* concentrate selectors, or intermediate feeders feeding on lush food in the rainy season (HOFMANN 1973).

Most long papillae of wild ruminants have no central artery, but two vertically ascending marginal arteries that supply the lateral edges of the papillae with capillaries (VOLLMERHAUS and SCHNORR 1968, in HOFMANN 1973). This arrangement is also seen in the red duiker and blue duiker. The capillaries ascending from the marginal artery are situated in the papillae occulta, reaching out towards the free surface of the papilla. Epithelial plugs and crests are thus formed between the capillaries, establishing intimate contact between basal cells and the blood system (HOFMANN 1973). Thus the effective thickness of the epithelium is greatly reduced in the forest duikers.

The arrangement, number, and development of subepithelial venules change with food quality, and hence differing fermentation and absorption rates (VOLLMERHAUS and SCHNORR 1968, in HOFMANN 1973). In the rumen papillae of red duiker and blue duiker, the venules form pouches around which the basal cells are arranged in a radiating manner, facilitating contact between the vascular wall and many epithelial cells.

HOFMANN (1973) found that concentrate selectors have a relatively large reticulum and that mucosal relief of the reticulum is dependent on food habits, and can vary exten-

sively between species. There is a stepwise transition from absorptive papillae to reticular crests (LANGER 1974). The reticular mucosa of both red duikers and blue duikers with their characteristically low mucosal crests and spatulate cornified papillae therefore exemplified the grasping-protective, non-abrasive mucosa of the concentrate-selector reticulum (HOFMANN 1973).

Physiology

Although acetic acid is the predominant VFA in all ruminants (HOPPE 1984; VAN HOVEN and BOOMKER 1985), relative proportions of VFA vary with diet composition. High concentrations of acetic and butyric acids are characteristic of extensive cell wall fermentation, while high propionic acids are characteristic of soluble carbohydrate fermentation. Concentrate foods thus lower acetic acid concentration relative to propionic and butyric acids (EADIE and MANN 1970; PRINS and GELEN 1971). This is correlated with pH, since acetate production is inhibited below a pH of 6.2 (OWENS *et al.* 1984; HOPPE *et al.* 1983). Very low methane levels characterize small concentrate selectors, and a resulting low metabolizable energy loss. Thus high acetate:low propionate levels suggest higher proportions of energy lost as methane (VAN HOVEN and BOOMKER 1981). Unsaturated fatty acids, commonly found in browse, inhibit methanogenic bacteria while favouring propionate production (HOPPE *et al.* 1983; BOOMKER 1981, 1983, 1984; VAN HOVEN and BOOMKER 1985). High concentrations of propionic acid in small ruminants inhibit methane production by channelling carbon and hydrogen into propionate. Thus, propionic acid is more efficiently utilized than acetic acid (BLAXTER 1967).

Very high relative levels of propionate were recorded in both duiker species; the blue duikers had significantly higher levels than the red duikers. ALLO *et al.* (1973) found that with increased grain fractions in the diet, acetic acid concentration decreased relative to that of butyric acid. This explains the high butyric acid levels found in the captive blue duiker fed on pelleted grains. Although lower acetic:propionic ratios, and thus higher propionic acid concentrations are found in concentrate selectors (GIESE and VAN GYLSWYK 1975; HOPPE 1977 *a, b*), the results obtained, especially for the blue duikers', are very high compared to other selective (and intermediate) feeders. HOPPE (1977 *a, b*) and HOPPE *et al.* (1977) found that smaller species of antelope select rich diets and the high concentrations of propionic acid is indicative of low microbial cellulolytic activity.

Concentrate selectors have high fermentation rates (HOPPE *et al.* 1983; HOPPE 1984; VAN HOVEN and BOOMKER 1985), and those of the blue duiker and the red duiker approximate those of the suni (HOPPE and GWYNNE 1978) and dik dik (HOPPE *et al.* 1983). Because of the highly papillated rumen in blue duikers and red duikers, absorption rate is fast.

The caecum provides a constant temperature and pH for the maintenance of complex microbial populations (ULYATT *et al.* 1975). Since caecal volume relative to rumenoreticular volume is high in concentrate selectors, DRESCHER-KADEN (1977) and HOPPE (1984) hypothesized that caecal digestion is important in selective feeders. PRINS *et al.* (1984) and VAN HOVEN and BOOMKER (1985) claim that ruminal VFAs are less important in satisfying the energy requirements of concentrate selectors than nongeneralist feeders, concentrate selectors must absorb nutrients from the gastro-intestinal tract beyond the rumen to satisfy energy demands. The concentration of VFAs present in the caecum of blue duikers is higher than that in the rumen, but the volume of the caecum is much smaller than that of the rumen, making it less important overall but not insignificant. The relative composition of VFAs in the caecum and rumen indicates greater fibre utilization in the caecum, and parallels the results obtained by BOOMKER (1983) for grey duiker. Because of the high fermentation rates in the small selectors, protein and carbohydrates that are easily fermentable will be more rapidly absorbed than fibre, and thus fibre not utilized in the rumen will be digested in the hindgut (BOOMKER 1984; KAY *et al.* 1980; MALOY *et al.* 1982).

Recently, DEHORITY and VARGA (1991) have demonstrated the presence and density of bacterial and fungal members in the ruminal and caecal contents of blue duikers, which aid digestion. Total bacterial numbers differed in the caecum between diets, *i.e.* $1,064 \times 10^6$ bacteria/g for animals fed high-forage diet compared with 166×10^6 for those fed high-concentrate diet. Ruminal cellylolytic bacterial numbers were considerably higher than in impalas, *Aepycerus melampus* and springbok, *Antidorcas marsupialis* (GIESE and VAN GYLSWYK 1975), which may be associated with folivory in the blue duiker.

Acknowledgements

We wish to thank the Foundation for Research Development and the University of Natal for funding the research programme. We thank the Natal Parks Board for assistance in the capture and maintenance in captivity respectively of the red duikers and blue duikers.

Zusammenfassung

Morphologie des Pansens und Produktion von flüchtigen Fettsäuren bei Blauducker (Cephalophus monticola) und Rotducker (Cephalophus natalensis)

Die Anatomie des Pansens ist bei Blauduckern und Rotduckern sehr ähnlich. Bei beiden Arten ist der Pansen ein einfacher, plesiomorpher, mit Blindsäcken versehener, S-förmiger Schlauch, dessen Ostien groß und bei dem die Pansensäulen schwach ausgebildet sind. Diese Spezialisierungen erleichtern den schnellen Durchgang des Nahrungsbreies. Bei beiden Arten sind die Pansen dicht mit pilzförmigen, hochgradig durchbluteten Papillen besetzt, um die Absorption zu erleichtern. Viele Anpassungen sind charakteristisch für Verwender energiereicher Nahrung.

Die Gesamtkonzentration flüchtiger Fettsäuren ist beim Rotducker niedriger als beim Blauducker. Die Propionsäure- und Buttersäurekonzentration ist jedoch beim Blauducker höher, während die Essigsäurekonzentration wiederum beim Rotducker höher ist. Im Blinddarm des Rotduckers ist die Konzentration flüchtiger Fettsäuren (besonders Essigsäure) höher als beim Blauducker, trägt jedoch wahrscheinlich weniger Energie zum Stoffwechsel bei, wegen der geringeren Größe des Blinddarms im Vergleich zum Pansen.

References

- ALLO, A. A.; OH, J. H.; LANGHURST, W. H.; CONNOLLY, G. E. (1973): Volatile fatty acid production in the digestive system of deer and sheep. *J. Wildl. Manage.* **37**, 202–211.
- BLAXTER, K. L. (1967): The energy metabolism of ruminants. London: Hutchinson.
- BOOMKER, E. A. (1981): A study of the digestive processes of the common duiker *Sylvicapra grimmia*. M. Sc. thesis, University of Pretoria, Pretoria, South Africa.
- BOOMKER, E. A. (1983): Volatile fatty acid production in grey duiker *Sylvicapra grimmia*. *A. Afr. Anim. Sci.* **13**, 33–35.
- BOOMKER, E. A. (1984): Rumen gas composition, fermentation rates, and carbohydrate digestion in grey duiker, *Sylvicapra grimmia*. *S. Afr. J. Wildl. Res.* **14**, 123–126.
- BOWLAND, A. E. (1991): The ecology and conservation of blue duiker and red duiker in Natal. Ph. D. thesis, University of Natal, Pietermaritzburg, South Africa.
- DEHORITY, B. A.; VARGA, G. A. (1991): Bacterial and fungal numbers in ruminal and cecal contents of the blue duiker (*Cephalophus monticola*). *Appl. Environ. Microbiol.* **57**, 469–472.
- DEMENT, M. W. (1982): The scaling of ruminoreticulum size with body weight in East African ungulates. *Afr. J. Ecol.* **20**, 43–47.
- DOBSON, A. (1970): Absorption of tritiated water and ethanol from bovine rumen limited by blood flow. *Fed. Proc.* **29**, 529.

- DRESCHER-KADEN, U. (1977): Energy supply of chamois: microbial fermentation of natural food in rumen and caecum during summer and winter in the Alps. Proc. XIII Int. Congress of Game Biologists – Atlanta. Washington D.C.: The Wildlife Soc.
- EADIE, J. M.; MANN, S. O. (1970): Development of the rumen microbial population: high starch diets and instability. In: Physiology of digestion and metabolism in the ruminant. Ed. by A. T. PHILLIPSON. Newcastle-upon-Tayne: Oriel Press.
- ENGELHARDT, W. VON (1981): Some physiological aspects of the digestion of poor quality, fibrous diets in ruminants. Agriculture and Environm. **6**, 145–152.
- FAURIE, A. S. (1990): Aspects of nutrition and metabolism in red duikers (*Cephalophus natalensis*) and blue duikers (*Philantomba monticola*) in Natal. M. Sc. thesis, University of Natal, Pietermaritzburg, South Africa.
- GIESE, D.; VAN GYLSWYK, N. O. (1975): A study of feeding types and certain rumen functions in six species of South African wild ruminants. J. Agric. Sci. Camb. **85**, 75–83.
- HOFMANN, R. R. (1968): Comparison of rumen and omasum structure in East African game ruminants in relation to their feeding habits. In: Comparative nutrition of wild animals. Ed. by M. A. CRAWFORD. Symp. Zool. Soc. Lond. **21**, 179–194.
- HOFMANN, R. R. (1973): The Ruminant Stomach. Nairobi: East African Literature Bureau.
- HOFMANN, R. R. (1983): Adaptive changes in gastric and intestinal morphology in response to different fibre contents in ruminant diets. Bull. Roy. Soc. New Zealand **20**, 51–58.
- HOPPE, P. P. (1977 a): Comparison of voluntary food and water consumption and digestion in Kirk's dik-dik and suni. E. Afr. Wildl. J. **15**, 41–48.
- HOPPE, P. P. (1977 b): Rumen fermentation and body weight in African ruminants. Proc. XIII Int. Congress of Game Biologists. Washington, D.C.: The Wildlife Soc.
- HOPPE, P. P. (1984): Strategies of digestion in African herbivores. In: Herbivore nutrition. Ed. by F. M. C. GILCHRIST and R. I. MACKIE. Craighall: Science Press.
- HOPPE, P. P.; GWYNNE, M. D. (1978): Food retention time in the digestive tract of the suni antelope. Säugetierkd. Mitt. **26**, 236–237.
- HOPPE, P. P.; QUORTRUP, S. A.; WOODFORD, M. H. (1977): Rumen fermentation and selection in East African sheep, goats, Thompson's gazelle, Grant's gazelle and impala. J. Agric. Sci. Camb. **89**, 129–135.
- HOPPE, P. O.; HOVEN, W. L. VAN; ENGELHARDT, W. VON; PRINS, R. A.; LANKHORST, W.; GWYNNE, N. E. (1983): Pregastric and caecal fermentation in dik-dik (*Madoqua kirkii*) and suni (*Nestotragus moschatus*). Comp. Biochem. Physiol. **75 A**, 517.
- HOUP, T. R. (1970): Transfer of urea and ammonia to the rumen. In: Physiology of digestion and metabolism in the ruminant. Ed. by A. T. PHILLIPSON. Newcastle-upon-Tayne: Oriel Press.
- HOVEN, W. VAN; BOOMKER, E. A. (1981): Feed utilization and digestion in the black wildebeest (*Connochaetes grou* Zimmerman, 1780) in the Golden Gate Highlands National Park. S. Afr. J. Wildl. Res. **11**, 35–40.
- HOVEN, W. VAN; BOOMKER, E. A. (1985): Digestion. In: Bioenergetics of wild herbivores. Ed. by R. J. HUDSON and R. G. WHITE. Florida: CRC Press.
- HUME, I. D.; WARNER, A. C. I. (1980): Evolution of microbial digestion in mammals. In: Digestive physiology and metabolism in ruminants. Ed. by Y. RICKEBUSCH and P. THIVEND. Westport, Connecticut: A.V.I.
- KAY, R. B. N.; ENGELHARDT, W. VON; WHITE, R. G. (1980): The digestive physiology of wild ruminants. In: Digestive physiology and metabolism in ruminants. Ed. by Y. RICKEBUSCH and P. THIVEND. Westport, Connecticut: A.V.I.
- KELLOG, D. W. (1969): Analysis of rumen fluid volatile fatty acids by chromatography by Porapak Q.S.J. Dairy Sci. **52**, 1690–1692.
- KREULEN, D. A.; HOPPE, P. O. (1979): Diurnal trends and relationship to forage quality of ruminal volatile fatty acid concentration, pH and osmolarity in wildebeest on dry range in Tanzania. Afr. J. Ecol. **17**, 53–63.
- LANGER, P. (1974): Stomach evolution in the Artiodactyla. Mammalia **38**, 295–314.
- MALOY, G. M. O.; CLEMENS, E. T.; KARMAN, J. M. Z. (1982): Aspects of digestion and *in vitro* rumen fermentation rate in six species of East African wild ruminants. J. Zool. (London) **197**, 345–353.
- OWENS, F. N.; WEAKLEY, D. C.; GOETSCH, A. L. (1984): Modification of rumen fermentation to increase efficiency of fermentation and digestion in the rumen. In: Herbivore nutrition. Ed. by F. M. C. GILCHRIST and R. I. MACKIE. Craighill: Science Press.

- PARRA, R. (1978): Comparison of foregut and hindgut fermentation in herbivores. In: Ecology of arboreal folivores. Ed. by G. G. MONTGOMERY. Washington, D.C.: Smithsonian Inst. Press.
- PRINS, R. A.; GEELLEN, M. J. H. (1971): Rumen characteristics of red deer, fallow deer and roe deer. *J. Wildl. Manage.* **35**, 573-680.
- PRINS, R. A.; LANKHORST, A.; HOVEN, W. VAN (1984): Gastrointestinal fermentation in herbivores and the extent of plant cell wall digestion. In: Herbivore nutrition. Ed. by F. M. C. GILCHRIST and R. I. MACKIE. Craighall: Science Press.
- ROBBINS, C. T. (1983): Wildlife feeding and nutrition. New York: Academic Press.
- ULYATT, M. S.; DELLOW, D. W.; REID, C. S. W.; BAUCHOP, T. (1975): Structure and function of the large intestine of ruminants. In: Digestion and metabolism in the ruminant. Ed. by I. W. McDONALD and A. C. I. WARNER. Armidale: University of New England.

Authors' Address: Ms ALIDA S. FAURIE and Prof. M. R. PERRIN, Department of Zoology and Entomology, University of Natal, Private Bag X01, Scottsville, Pietermaritzburg 3209, Natal, South Africa.

ZOBODAT - www.zobodat.at

Zoologisch-Botanische Datenbank/Zoological-Botanical Database

Digitale Literatur/Digital Literature

Zeitschrift/Journal: [Mammalian Biology \(früher Zeitschrift für Säugetierkunde\)](#)

Jahr/Year: 1995

Band/Volume: [60](#)

Autor(en)/Author(s): Perrin Michael R., Faurie Alida S.

Artikel/Article: [Rumen morphology and volatile fatty acid production in the Blue duiker \(*Cephalophus monticola*\) and the Red duiker \(*Cephalophus natalensis*\) 73-84](#)