

Weeksella virosa HOLMES et al., 1987
colonised epidermal cysts
in *Hyla crepitans* WIED-NEUWIED, 1824
(Anura: Hylidae)

Von *Weeksella virosa* HOLMES et al., 1987 besiedelte epidermale Zysten
von *Hyla crepitans* WIED-NEUWIED, 1824
(Anura: Hylidae)

ANDREAS HASSL & ANGELIKA URL
& BARBARA REBEL-BAUDER

KURZFASSUNG

An den ersten (innersten) Fingern beider Vorderextremitäten eines aus Venezuela stammenden Exemplars des Laubfrosches *Hyla crepitans* WIED-NEUWIED, 1824, wurden etwa 5 mm große, epidermale Zysten gefunden. Im Zuge der mikrobiologischen Untersuchung des Zysteninhalts konnte nur eine Keimart, das Bakterium *Weeksella virosa* HOLMES et al., 1987 sicher festgestellt werden. Diese aeroben, gram negativen Stäbchen aus der Gruppe der Pseudomonaden sind ubiquitäre, boden- und wasserbewohnende Bakterien, von denen bekannt ist, daß sie opportunistisch immunsupprimierte oder traumatisierte Wirbeltiere infizieren können und zur Sepsis führen. Offenbar besitzt das Bakterium auch die Befähigung zur Besiedlung von Zysten und wahrscheinlich auch die zur Bildung nekrotischer Herde im Epithel von ansonsten adspektorisch gesund erscheinenden Froschlurchen.

ABSTRACT

A specimen of the tree frog, *Hyla crepitans* WIED-NEUWIED, 1824 collected in Venezuela exhibited epidermal cysts of about 5 mm diameter on the first (innermost) digit of each foreleg. Microbiological examination of the cyst contents demonstrated one type of germ only, the bacterium *Weeksella virosa* HOLMES et al., 1987. These aerobic, gram negative, *Pseudomonas*-related rods are ubiquitous soil and water inhabiting bacteria which are known to be opportunistically infectious to immunosuppressed or traumatised vertebrates in which they lead to sepsis. *Weeksella* is apparently able to colonise cysts and, probably, to form necrotic foci in the epithelium of otherwise apparently healthy anurans.

KEY WORDS

Bacteria: Cytophaga-Flexibacter-Bacteroides: *Weeksella virosa*, opportunistic bacteria, immunodeficiency, veterinary microbiology, infectious disease, amphibian decline, Amphibia, Anura, Hylidae, *Hyla crepitans*

INTRODUCTION

World-wide, some populations of amphibians are rapidly declining; this phenomenon was primarily recognised in the 1980s (BLAUSTEIN & WAKE 1990). Considerably involved in this amphibian decline are such infectious diseases, which are a consequence of immunosuppression due to increasing environmental stress (CAREY et al. 1999; GRILLITSCH 2000). In amphibians, examples of this type of infectious agents, so-called opportunistic germs, are known from bacteria, e.g., *Aeromonas* sp. (CAREY & BRYANT 1995; TAYLOR et al. 1999),

Pseudomonas sp. (BRODKIN et al. 1992), and from fungi, e.g., *Basidiobolus* sp. (GROFF et al. 1991), and *Saprolegnia* sp. (LEFCORT et al. 1997). Nevertheless, little is known about opportunistic germs, which are usually ubiquitous and free-living or harmlessly colonise vertebrates, but may become even life-threatening in immunodeficient hosts (e.g., WALOCHNIK et al. 1999).

We report on the findings made in a tree frog handicapped by epidermal cysts which were colonised by an opportunistic bacterium.

MATERIALS AND METHODS

In autumn 1999, some specimens of the neotropical tree frog, *Hyla crepitans* WIED-NEUWIED, 1824 caught at Valencia (Carabobo / Venezuela) were imported to Austria. During the initial medical examination, one male individual, caught in a sewage pond, presented impressive skin cysts on the first (innermost) digit of each forelimb (fig. 1). The specimen settled down miserably in the quarantine terrarium and was seriously handicapped in its behaviour such as locomotion or foraging. Thus, after a few days of observation, the frog was euthanised applying MS 222 Sandoz™ an anesthetic for fishes and amphibians (CLOSE et al. 1997) due to animal protection considerations. The carcass was stored at 4°C and twelve hours post mortem the skin of the frog's hands was disinfected with ethanol and both cyst cavities were rinsed with sterile phosphate-buffered salt solution (0.01 M) by injection and sucking. Samples of this wash solution were differently pre-incubated for bacteria enrichment and spread over several culture plates, appropriate for the cultivation of a broad spectrum of bacte-

ria, including entero- and mycobacteria. Moreover, the wash solution was checked for parasites, including Apicomplexa, amoebas, Microsporidia, Myxosporidia, "worms", and all kinds of fungi by appropriate staining techniques, like Giemsa staining, trichrome stain, Heidenhain- and calcofluor stain. After that, the frog was frozen at -20°C for later histopathological examination. Tissue samples from both fingers, liver, heart, lungs, kidney, and from the gastrointestinal tract were fixed in 7% neutral-buffered formalin and embedded in paraffin-wax. Three µm sections were stained with hematoxylin/eosin according to standard procedures. Additionally, Gram staining was performed for detection of bacteria, Gomori methenamin silver staining for detection of fungi.

On Columbia culture plates, a small number of yellow and white colonies were seen after 24 hours of incubation at 28°C. Four typical colonies were cloned, stained according to Gram, and typed by enzymatic profiling (api 20 NE and api 20 E, bio-Merieux™, Vienna, Austria).

RESULTS

All bacteria colonies isolated grew on the unselective Columbia agar plates, whereas all plates for a more selective cultivation remained sterile. The enzymatic profiling identified only one type of bacterium with acceptable probability (80.3 %): *Weeksellia virosa* HOLMES et al., 1987; type strain: NCTC 11634, nomenclature according to the Validation list No. 23, Internat. J. Syst. Bacteriol., (1987) 37: 179. Two more kinds of bacteria were typed but they had insufficiently low selectivity values (20% and 40%): *Flavimonas oryzihabitans* KODAMA et al., 1985, and *Ochrobactrum anthropi* HOLMES et al., 1988. All bacteria turned out to be gram negative, short rods in the Gram-staining, closely related to *Pseudomonas* sp. The longitudinal section through the distal region of the finger shows a well-demarcated cyst lined by multilayered epithelium

within the subcutis. Focally, there is moderate chronic purulent inflammation with epithelial necrosis. Briefly, the histopathological examination resulted in the finding of epidermal, non-cancerous cysts along with a chronic purulent inflammation of the connective tissue. The etiology of the cyst formation could not be elucidated, the purulent inflammation may be explained as a residual of a local, acute inflammation due to bacterial invasion (fig. 2). In this tissue, bacteria - coccoid rods - were seen occasionally, while some necrotic foci were found in the epithelium. In addition, a post-mortal colonization of the liver blood vessels by fungi (*Phaeohyphomycetes*) was detected. Some undetermined nematodes of the order Rhabditida lived in the body cavern.

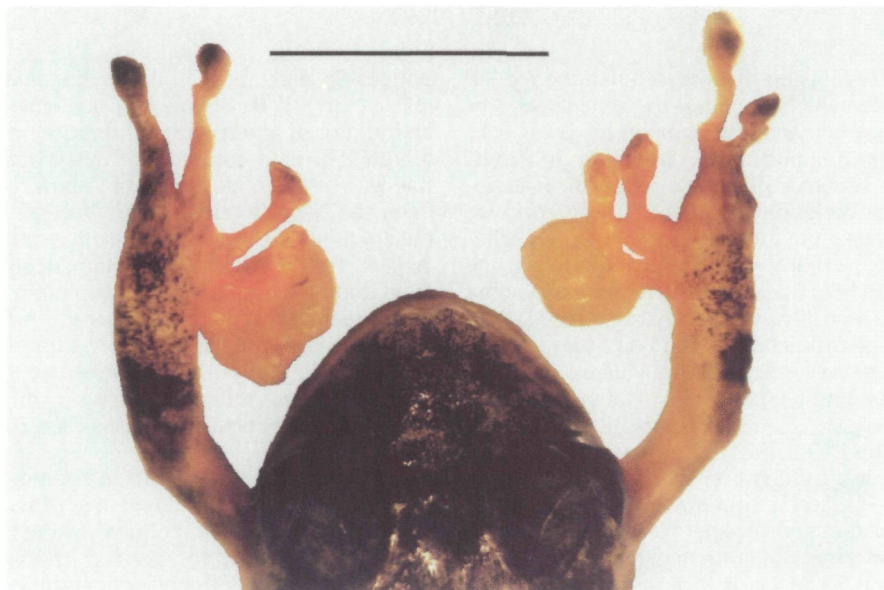

Fig. 1: Epidermal cysts of the first (innermost) digit of each foreleg in the Neotropical treefrog *Hyla crepitans* WIED-NEUWIED, 1824. Dorsal view. Bar represents 1 cm.

Abb. 1: Epidermale Zysten auf dem ersten (innersten) Finger beider Vorderextremitäten beim neotropischen Laubfrosch *Hyla crepitans* WIED-NEUWIED, 1824. Dorsalansicht. Balkenlänge entspricht 1 cm.

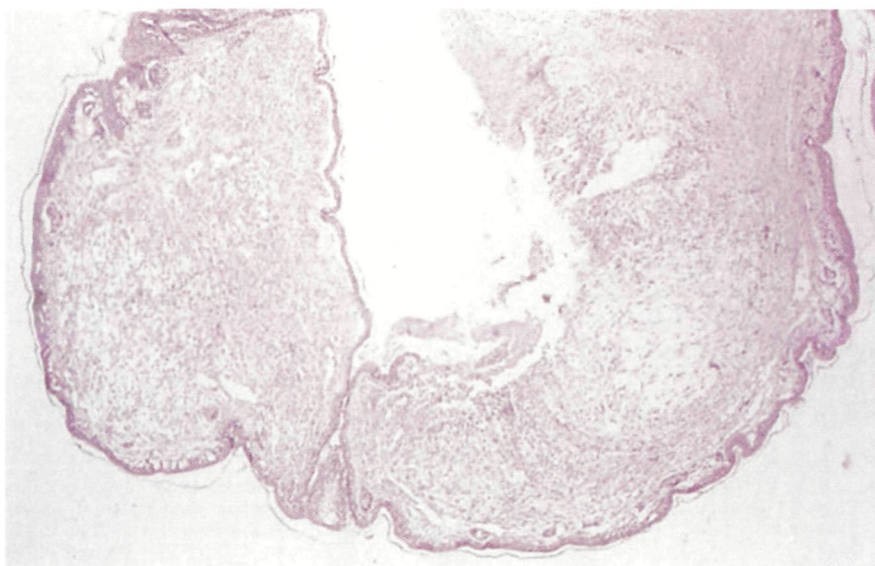


Fig. 2: Longitudinal section through the finger cyst of *Hyla crepitans* WIED-NEUWIED, 1824. Stain: hematoxylin-eosin, magnification factor: 32.

Abb. 2: Längsschnitt durch eine Fingerzyste von *Hyla crepitans* WIED-NEUWIED, 1824. Hämatoxylin-Eosin Färbung; 32-fache Vergrößerung.

DISCUSSION

It is generally accepted that the red leg disease, which is caused by some species of *Aeromonas* and *Pseudomonas*, is a very common opportunistic infection in frogs. Some bacteria, like those related to *Pseudomonas* including the genus *Weeksella*, are common, ubiquitous environmental inhabitants, usually harmlessly colonising the skin and the intestine of vertebrates. In some cases, not always clearly associated with immunodeficiency of the host, these bacteria become virulent and may cause pneumonia, meningitis, peritonitis, and sepsis. E. g., *Bergeyella* (= *Weeksella*) *zooheicum* HOLMES et al., 1987 is known as coloniser of wounds after dog bite in man.

Weeksella bacteria are inhabitants of soil, water, and sewage; they are non-motile, non-sporulating, gram negative, plump rods, about $0.5 \times 1 \mu\text{m}$ in size, and able to cause purulent inflammation foci (HOLMES et al. 1986). These attributes correspond precisely to our histopathological findings in the cyst epithelium of the tree frog. Thus, we conclude that the frog (i.e., the cyst epithelium) was likely to be infected with *Weeksella virosa* HOLMES et al., 1987, whereas the cyst cavities were certainly colonised by this opportunist.

Infection of free-living amphibians by opportunistic germs is clinically hardly

noticeable and, thus, is rarely documented (HASSL 2000). *Weeksella* was not known as an initiator of any tissue proliferation in vertebrates, or as a coloniser of cyst volumes, nor as a usual opportunist in Anura. However, the identification of this bacterium in the contents of the cysts is a strong argument for its ability to live opportunistically in frogs too. The hypotheses to explain a supposed increase in the frog's susceptibility to *W. virosa* may read as environmental changes due to pollution cause neuroendocrine changes reflecting "stress", which in turn cause immunosuppression (CAREY et al. 1999).

Neoplasms seem to occur sporadically in amphibians, but they have been found in amphibians living in polluted waters and they are expected to develop more frequently under the influence of certain chemicals (CRAWSHAW 1992), and maybe through an interplay between chemicals and opportunistic germs. The striking appearance of two symmetrically situated cysts on both inner fingers cannot solely be attributed to this bacterial infection. It may be explained by the possible pathway of invasion: either via the symmetrically located nuptial pad glands or via self-inflicted microlesions due to mismatching copulation attempts.

ACKNOWLEDGEMENTS

The authors thank Mr. Christian PROY (Netting, Austria) for generously leaving the tree frog to us for all

kinds of examinations, and Mrs. Susanne RUDNICKI (Vienna, Austria) for excellent technical advice.

REFERENCES

- BLAUSTEIN, A. R. & WAKE, D. B. (1990): Declining amphibian populations. A global phenomenon? - Trends in Ecology and Evolution, London; 5: 203-204.
- BRODKIN, M. A. & SIMON, M. P. & DESANTIS, A. M. & BOYER, K. J. (1992): Response of *Rana pipiens* to graded doses of the bacterium *Pseudomonas aeruginosa*. - J. Herpetol., Phoenix; 26 (4): 490-495.
- CAREY, C. & BRYANT C. J. (1995): Possible interrelations among environmental toxicants, amphibian development, and decline of amphibian populations. - Environmental Health Perspectives, Research Triangle Park; 103 (4): 13-17.
- CAREY, C. & COHEN, N. & ROLLINS-SMITH, L. (1999): Amphibian declines: an immunological perspective. - Developmental Comp. Immunol., Corvallis; 23: 459-472.
- CLOSE, B. & BANISTER, K. & BAUMANS, V. & BERNOTH, E.-V. & BROMAGE, N. & BUNYAN, J. & ERHARDT, W. & FLECKNELL, P. & GREGORY, N. & HACKBARTH, H. & MORTON, D. & WARWICK, C. (1997): Recommendations for euthanasia of experimental animals: Part 2. - Laboratory animals, London; 31: 1-32.
- CRAWSHAW, G. J. (1992): The role of disease in amphibian decline. In: BISHOP, C. A. & PETTIT, K. E. (Eds): Declining Canadian amphibian populations: designing a national monitoring strategy. - Canadian Wildlife Service Occ. Pap., Ottawa; 76: 60-62.
- GRILLITSCH, B. (2000): Why amphibians are in danger; pp. 228-235. In: HOFRICHTER, R. (Ed.):

Amphibians. The world of frogs, toads, salamanders and newts; Buffalo, New York (Firefly Books).

GROFF, J. M. & MUGHANNAM, A. & McDOWELL, T. S. & WONG, A. & DYKSTRA, M. J. & FRYE, F. L. & HEDRICK, R. P. (1991): An epizootic of cutaneous zygomycosis in cultured dwarf African clawed frogs (*Hymenochirus curtipes*) due to *Basidiobolus ranarum*.- J. Med. Vet. Mycol., Oxford; 29: 215-223.

HASSL, A. (2000): Disease and Immunology; pp. 108-110. In: HOFRICHTER, R. (Ed.): Amphibians. The world of frogs, toads, salamanders and newts; Buffalo, New York (Firefly Books).

HOLMES, B. & STEIGERWALT, A. G. & WEAVER, R. E. & BRENNER, D. J. (1986): *Weeksellia virosa* gen. nov., sp. nov. (formerly group IIF) found in human clinical specimens.- Syst. Appl. Microbiol., Jena; 8: 185-190.

LEFCORT, H. & HANCOCK, K. A. & MAUR, K. M. & ROSTAL, D. C. (1997): The effects of used motor oil, silt, and the water mold *Saprolegnia parasitica* on the growth and survival of mole salamanders (genus *Ambystoma*).- Arch. Environ. Contam. Toxicol., New York; 32: 383-388.

TAYLOR, S. K. & WILLIAMS, E. S. & MILLS, K. W. (1999): Effects of malathion on disease susceptibility in Woodhouse's toads.- J. Wildlife Disease, Laramie; 35: 536-541.

WALOCHNIK, J. & HASSL, A. & SIMON, K. & BENYR, G. & ASPÖCK, H. (1999): Isolation and identification by partial sequencing of the 18S ribosomal gene of free-living amoebae from necrotic tissue of *Basiliscus plumifrons* (Sauria: Iguanidae).- Parasitol. Res., Heidelberg; 85: 601-603.

DATE OF SUBMISSION: March 5th, 2001

Corresponding editor: Heinz Grillitsch

AUTHORS: Univ. Prof. Dr. Andreas HASSL, Micro-Biology Consult, Ameisgasse 63/4/12, A- 1140 Vienna, Austria and Clinical Institute of Hygiene, Kinderspitalgasse 15, A-1095 Vienna, Austria < e-mail: andreas.hassl@univie.ac.at >; Mag. Dr. Angelika URL, Mag. Dr. Barbara REBEL-BAUDER, Institute of Pathology and Forensic Veterinary Medicine, University of Veterinary Medicine, A-1210 Vienna, Austria.

ZOBODAT - www.zobodat.at

Zoologisch-Botanische Datenbank/Zoological-Botanical Database

Digitale Literatur/Digital Literature

Zeitschrift/Journal: [Herpetozoa](#)

Jahr/Year: 2002

Band/Volume: [14_3_4](#)

Autor(en)/Author(s): Hassl Andreas R., Url Angelika, Rebel-Bauder Barbara

Artikel/Article: [Weeksella virosa HOLMES et al., 1987 colonised epidermal cysts in Hyla crepitans WIED-NEUWIED, 1824 127-131](#)