

Cephalic respiratory hamartoma in *Podarcis carbonelli* PEREZ MELLADO, 1981: A case report

A hamartoma is a rare benign, focal malformation reported in mammals (including humans) and other vertebrates. It can develop in all parts of the body and is classically defined as an aggregation of cells or tissues, which are normal for the given anatomical site but abnormal in amount, ratio or distribution (WILLIS 1968). Different from malignant tumors, hamartomas grow at the same rate as the surrounding tissues. Most cases are asymptomatic and remain undetected but others may be evident externally and even physically interfere with the

functions of the organ they develop in. In mammals, the most common hamartomas occur in the respiratory tract, mainly lungs and nasal cavity (TERRIES et al. 1993). They usually arise from connective tissue and are formed of cartilage, fat and connective tissue cells, although they may include many other cell types. In contrast, reports of hamartomas in non-mammalian vertebrates are extremely rare (i.e., birds, STEINBERG 2006), but this likely results from lack of research rather than real absence. Below the authors report a case of hamartoma in a reptile.

During systematic herpetological sampling conducted near Torreira, a coastal locality in northwestern Portugal (40.763696° N, 8.710090° E), a specimen of *Podarcis carbonelli* PEREZ MELLADO, 1981, a lacertid species endemic to the western Iberian Peninsula (SÁ-SOUSA et al. 2009), was collected from an area of sand dunes on 18 February, 2002. The specimen, an adult male, measured 48.78 mm snout-vent length (SVL) and weighed 2.85 g. According to these measurements and to the phenology of the species in the area (CARRETERO et al. 2006) this lizard appeared sexually mature and ready to participate in the breeding season with at least 18 months of age.

The individual presented an unusual external protuberance on the prefrontal area of the pileus (Fig. 1), whose nature recommended further histological analysis. Besides this teratology described below, the specimen was otherwise normal in terms of shape and coloration while the gonads and other internal organs were well developed (CARRETERO et al. 2006). No other lizards with abnormalities were recorded in this population despite more than 300 individuals collected in this locality between 2001 and 2005.

The specimen was taken to the lab and euthanized by intraperitoneal injection of 0.7 % MS222 (tricaine methanesulfonate) followed by another injection of 50 % MS222 as already described (CONROY et al. 2009). An excisional biopsy of the nasal area was immersed in 10 % neutral buffered formalin and sent to the Veterinary Anatomical Pathology unit, Echevarne Laboratories (Barcelona), where samples of the mass were embedded in paraffin, sectioned at




Fig. 1: Lateral (top) and dorsal (bottom) view of the adult male *Podarcis carbonelli* PEREZ MELLADO, 1981, from near Torreira, northwestern Portugal. Note the protuberance emerging from the left prefrontal area of the pileus which was determined to be a hamartoma after histological examination.

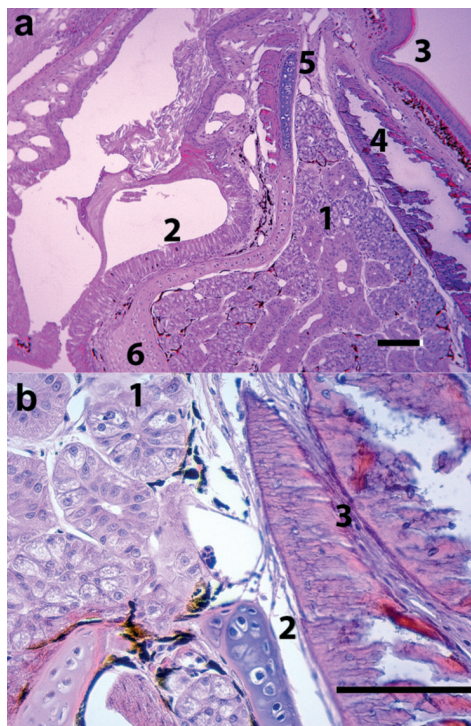


Fig. 2. Histological views of the hamartoma. Length of horizontal scale bars represents 100 µm. A - Several tissues such as glandular epithelium (1), respiratory epithelium (2), keratinizing stratified epithelium (3), bone (4), cartilage (5) and connective tissue (6) can be observed. B - detail of the glandular epithelium (1), cartilage cells (2) and connective tissue (3).

3 µm, and stained with hematoxylin and eosin.

The histological examination revealed that the protruding structure was composed of multiple tissue types appearing in a disorganized manner. The tissues comprised glandular epithelium, ciliated respiratory epithelium rich in mucous cells, keratinizing stratified epithelium, bone, cartilage and connective tissue (Fig. 2), including arteriolar, capillary and venous vascular structures and nerve fibres. In addition, multifocal melanocytes were present, especially at the base of glandular structures in apposition with the *lamina propria*. All tissues appeared well differentiated. Respiratory type epithelium was organized around a

luminal cavity and appeared in continuity with the keratinizing stratified epithelium in a progressive transition. The entire structure appeared covered by skin tissue with a slightly acanthotic epidermis and a thin dermis. In accordance with the histological description, the lesion was identified as a hamartoma.

After the histological analysis, the presence of the three types of germinal tissue (endodermal, mesodermal and ectodermal) allows for ascribing the structure to a teratoma. These tissues commonly originate from germinal, pluripotent cells, teratomas being frequent in reproductive (testicular or ovarian) tissues. For instance, ovarian teratomas have been described for

the turtles *Trachemys scripta* (THUNBERG in SCHOEPPF, 1792) (NEWMAN et al. 2003; HIDALGO-VILA et al. 2006) and *Testudo hermanni* GMELIN, 1789 (MARTORELL et al. 2009). In lizards, there are similar reports for *Aspidoscelis uniparens* (WRIGHT & LOWE, 1965) (TOCIDLOWSKI et al. 2001) and *Brachylophus fasciatus* (BRONGNIART, 1800) (WENGER et al. 2010). However, in the present case, the abnormal cell development corresponds to specialized tissues, which are spatially disorganized but mature and specific for the anatomical area they are found. Because of this, the abnormality is classified as a hamartoma. Remarkably, there is proliferation of supporting (cartilage, endodermal), respiratory (mesodermal) and cutaneous (ectodermal) tissue in an abnormal and disorganized manner surrounding a cystic structure. To the authors' knowledge, this is the first report of hamartoma in the reptile pathology.

Certainly, other cephalic proliferations occur in reptiles, such as normal cutaneous horns and pseudohorns (FRYE 1991), calcinosis cutis (HERNANDEZ-DIVERS & GARNER 2003), as well as teratologies related with incubation conditions (MARTÍNEZ-SILVESTRE & FRYE 2002), cutaneous or osseous neoplasms (DEEMING & FERGUSON 2011] and fibriceses (HUCHZERMAYER & COOPER 2000), all of them substantially differing from hamartomas in histological morphology and dynamics.

As in many other cases of hamartoma, the causes for that lesion in a particular wild individual are unknown. The area of collection of the lizard is included within a natural park harboring well conserved habitats devoid of obvious sources of environmental disturbance. Also, genetic causes (i.e., inbreeding, hybridization) are to be discarded because of the large population size and lack of barriers to gene flow and absence of syntopic *Podarcis* species to hybridize with (CARRETERO et al. 2006). As no other abnormal specimens were recorded in the area, despite sampling of numerous lizards, the presence of the lesion has to be considered an isolated case within this specific lizard population. Overall, the present finding suggests to consider hamartomas in the differential diagnostics of anomalies in reptiles.

ACKNOWLEDGMENTS: Thanks are due to D. Barbosa for field assistance. The sampling was supported by the project POCTI/BSE/45664/2002 of Fundação para a Ciência e a Tecnologia (FCT), Portugal. Miguel A. Carretero was supported by project NORTE-01-0145-FEDER-000007. Collecting and sampling permits (POA – 1.1/00021) were provided by the Instituto de Conservação da Natureza (ICN, Portugal).

REFERENCES: CARRETERO, M. A. & RIBEIRO, R. & BARBOSA, D. & SÁ-SOUSA, P. & HARRIS, D. J. (2006): Spermatogenesis in two Iberian *Podarcis* lizards: Relationships with male traits.- *Animal Biology*, Leiden; 56: 1-12. CONROY, C. J. & PAPENFUSS, T. J. & PARKER, J. & HAHN, N. E. (2009): Use of Tricaine Methanesulfonate (MS222) for euthanasia of reptiles.- *Journal of the American Association for Laboratory Animal Science*, Memphis; 48: 28-32. DEEMING, D. C. & FERGUSON, M. W. J. (2011): Physiological effects of incubation temperature on embryonic development in reptiles and birds; pp. 147-171. In: DEEM, S. L. & FERGUSON, M. W. J. (Eds.): *Egg incubation: its effects on embryonic development in birds and reptiles*. Cambridge (Cambridge University Press). FRYE, F. L. (1991): Biomedical and surgical aspects of captive reptile husbandry. Malabar (Krieger Publishing), pp. 637. HERNANDEZ-DIVERS, S. J. & GARNER, M. (2003): Neoplasia on reptiles with an emphasis on lizards.- *Veterinary Clinics of North America: Exotic Animal Practice*, Philadelphia; 6: 251-273. HIDALGO-VILA, J. & MARTÍNEZ-SILVESTRE, A. & DIAZ-PANIAGUA, C. (2006): Benign ovarian teratoma in a red eared slider (*Trachemys scripta elegans*).- *Veterinary Record*, London; 159: 122-123. HUCHZERMAYER, F. W. & COOPER, J. E. (2000): Fibrices, not abscess, resulting from a localized inflammatory response to infection in reptiles and birds.- *Veterinary Record*, London; 147: 515-517. MARTÍNEZ-SILVESTRE, A. & FRYE, F. L. (2002): A case of calcinosis cutis and pseudocutaneous horn in a captive red-eared slider (*Trachemys scripta elegans*).- *Boletín de la Asociación Herpetológica Española*, Madrid; 13: 45-48. MARTORELL, J. & SOTO, S. & BARRERA, S. & RAMIS, A. (2009): Ovarian teratoma in a Mediterranean tortoise.- *Compendium on Continuing Education for the Practicing Veterinarian*, Davis; 231: 193-196. NEWMAN, S. J. & BROWN, C. & PATNAIK, A. K. (2003): Malignant ovarian teratoma in a red eared slider (*Trachemys scripta elegans*).- *Journal of Veterinary Diagnostic Investigation*, Los Angeles; 15: 77-81. SÁ-SOUSA, P. & PÉREZ-MELLADO, V. & MARTÍNEZ-SOLANO, I. (2009): *Podarcis carbonelli*. The IUCN Red List of Threatened Species 2009: e.T61545A12512496. WWW document available at < <http://dx.doi.org/10.2305/IUCN.UK.2009.RLTS.T61545A12512496.en> > [last accessed: May 20, 2018]. STEINBERG, H. & PARÉ, J. A. & PAUL-MURPHY, J. (2006): A Dermal vascular hamartoma in a Sun Conure (*Aratinga solstitialis*).- *Journal of Avian Medicine and Surgery*, Teaneck; 20: 161-166. TERRIES, M. H. & BILLMAN, G. F. & PANSKY, S. M. (1993): Nasal hamartoma: case report and review of the literature.- *International Journal of Pediatric Otorhinolaryngology*, Amsterdam; 28: 83-88. TOCIDLOWSKI, M. E. & MERRILL, C. L. & LOOMIS, M. R. & WRIGHT, J. F. (2001): Teratoma in desert grassland whiptail lizards (*Cnemidophorus uniparens*).- *Journal of Zoo and Wildlife Medicine*, Yulee; 32: 257-259. WENGER, S. & SIMOVA-CURD, S. & GREST, P. & STEIN-

METZ, H. W. & HATT, J. M. (2010): Ovarian teratoma in a Fiji Island Banded Iguana (*Brachylophus fasciatus*) and a Green Iguana (*Iguana iguana*).- Journal of Herpetological Medicine and Surgery, Chester; 20, 20-23. WILLIS, R. A. (1968): Some unusual developmental heterotopias.- British Medical Journal, London; 3: 267-272.

KEY WORDS: Reptilia: Squamata: Sauria: Lacertidae: *Podarcis carbonelli*; veterinary medicine, hamartoma, teratology, pathology, diagnosis; Portugal

SUBMITTED: February 15, 2018

AUTHORS: Albert MARTINEZ-SILVESTRE ¹⁾, Daniel BORRAS ²⁾, Miguel A. CARRETERO (Corresponding author, < carretero@cibio.up.pt >) ³⁾

¹⁾ Catalanian Reptile and Amphibian Rescue Center (CRARC), 08783 Masquefa, Barcelona, Spain

²⁾ Veterinary Anatomical Pathology Unit. Echevarne Laboratories, C/ Provença 312, 08037 Barcelona, Spain

³⁾ CIBIO Research Centre in Biodiversity and Genetic Resources, InBIO, Universidade do Porto, Campus de Vairão, Rua Padre Armando Quintas, Nº 7. 4485-661 Vairão, Vila do Conde, Portugal

ZOBODAT - www.zobodat.at

Zoologisch-Botanische Datenbank/Zoological-Botanical Database

Digitale Literatur/Digital Literature

Zeitschrift/Journal: [Herpetozoa](#)

Jahr/Year: 2018

Band/Volume: [31_1_2](#)

Autor(en)/Author(s): Martinez-Silvestre Albert, Borrás Daniel, Carretero Miguel A.

Artikel/Article: [Cephalic respiratory hamartoma in Podarcis carbonelli PEREZ MELLADO, 1981: A case report 116-119](#)