

## *T cell accumulation in spleen and liver during murine Plasmodium vinckei malaria*

S. Neifer, J. Prada, U. Bienzle, P. G. Kremsner

### Introduction

Spleen and liver play a decisive role in *Plasmodium vinckei* malaria by clearing the parasitized red blood cells from the circulation (4, 16). It has previously been observed that both organs show a pronounced accumulation of macrophages (9, 12), accompanied by an increase of phagocytic activity (13) and an elevated production of reactive oxygen intermediates (3, 12) in malaria. Since immunity in murine malaria seems to be T cell dependent, involving both antibody and cell mediated mechanisms (2, 6, 8), it was of interest to study the changes in the T cell population of spleen and liver during *P. vinckei* malaria. In this paper, we have analysed the variation of mouse equivalent CD3, CD4, and CD8 positive T lymphocytes in both organs, by using immunohistochemistry and flow cytometry techniques.

### Materials and methods

#### Infection

Female Balb/c mice (Bundesgesundheitsamt, Berlin, Germany), 8 to 10 weeks old, were used in all experiments. Mice were infected by intraperitoneal injection of  $10^5$  *P. vinckei* parasitized erythrocytes resuspended in 100  $\mu$ l phosphate buffered saline (PBS). Starting 3 days after infection, thin blood smears were performed daily and stained with Giemsa stain for determination of parasitaemia. A room temperature of 25°C and a 12 h light-dark photoperiod were maintained during all the experiments. The mice were killed by CO<sub>2</sub> gas on day 0 (uninfected controls), on day 3 (patent parasitaemia around 0.1%), on day 5 (moderate parasitaemia: 5 – 15%) and on day 7 (marked clinical symptoms, parasitaemia 50 – 60%). Untreated mice died between day 7 and day 9. Spleen and liver were removed aseptically from controls and infected animals at the indicated time points. The organs were either shock frozen in liquid nitrogen for cryostat section and immunohistochemistry, or processed for immediate use in flow cytometry.

#### Immunohistological studies

Cryostat sections of biopsy material (8  $\mu$ m) were analysed with monoclonal antibodies using an alkaline phosphatase technique as previously described (11). Briefly, sections were dried overnight, fixed in acetone (10 min) and overlaid with the respective monoclonal antibody. The rat monoclonal antibodies used to identify murine T cell surface phenotypes were Thy1.2 (CD3 equivalent), L3T4 (CD4 equivalent) and Lyt2 (CD8 equivalent, all from Becton Dickinson, Heidelberg, Germany).

As diluent, RPMI 1640 medium (Seromed, Berlin, Germany) was used with 1% normal mouse serum. After two rinses with tris buffered saline (TBS; Merck, Darmstadt, Germany), the sections were incubated with alkaline phosphatase conjugated goat anti-rat polyclonal antibody (Medac, Hamburg, Germany) diluted in RPMI 1640 medium. Incubation was carried out for 30 min at room temperature for both steps. Thereafter, 50 mg sodium nitrite (Merck) dissolved in 1.25 ml distilled water and mixed with 0.5 ml 5% fuchsin solution (Merck), as well as 125 mg naphthole-As-biphosphate (Sigma, Heidelberg, Germany) dissolved in 1.5 ml dimethyl-formamide (Sigma), were added to 175 ml TBS containing 1313 mg 2-amino-2-methyl-1,3-propandiol (Merck) and 100 mg levamisole (Sigma). The sections were further incubated in this solution for 30 min, after washing with tap water, were counterstained with 0.1% Mayer's haematoxylin solution (Sigma) for 5 min.

Table 1:

Immunohistological findings in the spleen of Balb/c mice during the course of *P. vinckei* malaria<sup>1, 2, 3</sup>

| spc:<br>day | Thyl. 2 |      |    |    | L3T4 |      |    |    | Lyt2 |      |    |    |
|-------------|---------|------|----|----|------|------|----|----|------|------|----|----|
|             | RP      | PALS | FO | MZ | RP   | PALS | FO | MZ | RP   | PALS | FO | MZ |
| 0           | ++      | +++  | +  | +  | ++   | +++  | +  | +  | +    | ++   | ±  | ±  |
| 3           | ++      | +++  | +  | +  | ++   | +++  | ++ | +  | +    | ++   | ±  | ±  |
| 5           | ++      | +++  | +  | +  | +    | +++  | ++ | ±  | +    | ++   | ±  | ±  |
| 7           | +       | +++  | +  | +  | +    | ++   | +  | ±  | +    | ++   | ±  | ±  |

1) The investigated spleen compartments (spc) were: red pulp (RP), periarteriolar lymphocyte sheath (PALS), follicles (FO), and marginal zone (MZ).

2) Symbols +, - and ± indicate the marker density (two investigations of three mice each) using the following scale:

-: not detectable · ±: very low  
+: low · ++: moderate · +++: high.

3) The indicated days in the course of the *P. vinckei* infection correspond to the following parasitaemia: day 0 (controls): 0% day 3 (patent infection): approx. 0.1% · day 5: 5-15% · day 7: 50-60%.

for 5 min on ice. Leukocytes were counted and adjusted to 10<sup>6</sup> cells/ml for labelling. Cell suspensions were labelled with the appropriate monoclonal antibody (Thy1.2, L3T4, or Lyt2) using direct staining (100 µl cell suspension plus 10 µl fluorescein labelled antibody). Flow cytometry analysis was performed in a FACSCAN system from Becton Dickinson.

Results

The lymphocyte subpopulations in spleen and liver of *P. vinckei* infected mice were immunohistologically analysed by using antibodies against the T cell antigens Thy1.2 (CD3+, pan T cell marker), L3T4 (CD4+, T helper subset) and Lyt2 (CD8+, T cytotoxic/suppressor subset).

In the spleen, the red pulp and three distinct compartments of the white pulp, i. e. the periarteriolar lymphocyte sheath (PALS), the follicles and the marginal zone, were examined at day 0, 3, 5 and 7 of the *P. vinckei* infection. The results are summarized in Table 1. In the red pulp, the relative proportions of CD3+ and CD4+ T cells decreased in the course of the infection, whereas CD8+ T cells remained constant. In the PALS, only CD4+ cells decreased slightly when the parasitaemia reached 60%. The follicles showed an increase of CD4+ T cells in the early phase of infection followed by a decrease in the late phase. In the marginal zone, the proportion of CD4+ T cells markedly decreased in the course of infection.

Malaria pigment (haemozoin) deposition was observed with parasite densities higher than 5%. The number of secondary follicles increased during the course of infection. In all the examined mice, the increase in follicle size was considerable and associated with the appearance of large germinal centres. At parasitaemia > 50%, the architecture of the marginal zone changed, showing a decrease in width, accompanied by a decrease of CD4+ T cells, so that the marginal zone appeared to merge with the red pulp.

Flow cytometric analysis of spleen cells showed that the absolute number of spleen leukocytes increased from 5 × 10<sup>7</sup> to 31 × 10<sup>7</sup> (medians for n = 3 each) in the course of *P. vinckei* malaria, including all leukocyte fractions, but the relative proportions of the different lymphocyte subpopulations changed with the progress of infection. The results are summarized in Table 2.

In the liver, immunohistochemical analysis showed that the normal tissue contains very few lymphocytes in the sinusoids or in the periportal region, while the relative proportion of these cells increased considerably in the course of infection. Around the portal vein and in the sinusoids, the relative proportions of CD3+, CD4+ and CD8+ T cells were found to be markedly increased (Tab. 3). Figure 1 shows a typical increment of the number of CD3+ T cells observed in immunohistology of the liver of a mouse with approximately 60% parasitaemia. Pigment-loaded macrophages (granulated sediment, Fig. 1) in the liver sinusoids and adherent at venular endothelium were observed at parasitaemias > 5%.

Flow cytometry

Aseptically removed spleens were teased through fine stainless steel screens into 5 ml cold PBS with 2% bovine serum albumin (BSA). Cells were pelleted by centrifugation in cold PBS-BSA, 10 min, 1000 G. Erythrocytes were lysed by resuspending cell pellets in 2 ml of 0.017 M tris, 0.144 M NH<sub>4</sub>Cl, pH 7.3

Table 2:

Distribution (%) of spleen leucocytes from Balb/c mice during the course of *P. vinckei* malaria as observed in flow cytometry<sup>1, 2</sup>

| day | Thyl.2     | L3T4       | Lyt2      |
|-----|------------|------------|-----------|
| 0   | 43 (42-44) | 29 (26-30) | 10 (9-14) |
| 3   | 39 (39-43) | 33 (33-36) | 10 (8-12) |
| 5   | 31 (31-38) | 22 (19-26) | 9 (7-10)  |
| 7   | 29 (23-30) | 22 (20-24) | 9 (9-12)  |

1) The results are presented as medians and ranges for n = 3.

2) The indicated days in the course of the *P. vinckei* infection correspond to the following parasitaemias: day 0 (controls): 0% day 3 (patent infection): approx. 0.1% · day 5: 5-15% · day 7: 50-60%.

Table 3:

Immunohistological findings in the liver of Balb/c mice during the course of *P. vinckei* malaria<sup>1, 2, 3</sup>

| lic:<br>day | Thyl.2 |     | L3T4 |    | Lyt2 |    |
|-------------|--------|-----|------|----|------|----|
|             | PZ     | SI  | PZ   | SI | PZ   | SI |
| 0           | +      | +   | ±    | +  | -    | ±  |
| 3           |        | +   | ±    | +  | -    | +  |
| 5           | ++     | ++  | +    | ++ | -    | +  |
| 7           | ++     | +++ | +    | ++ | +    | +  |

1) The investigated liver compartments (lic) were the portal zone (PZ) and the sinusoids (SI).

2) Symbols +, - and ± indicate the marker density (two examinations of three mice each) using the following scale: - : not detectable · ±: very low · +: low · ++: moderate · +++: high.

3) The indicated days in the course of the *P. vinckei* infection correspond to the following parasitaemia: day 0 (controls): 0% day 3 (patent infection): approx. 0.1% · day 5: 5-15% · day 7: 50-60%.

## Discussion

Spleen and liver are organs which are directly involved in the primary host response to malaria. Marked hepatosplenomegaly is one of the common manifestations in human and murine malaria (10, 16).

When the *P. vinckei* infection became patent, the enlargement of the PALS was an initial change observed in the spleen involving cell number and distribution of lymphocytes. The number of T helper lymphocytes increased mainly in the follicles which developed germinal centres and recruited CD4+ T cells. These T helper cells associated with the germinal centre are typically L3T4+/Thy1.2- (5); their functional significance is not known. The initial cellular changes may reflect an attempt to develop antimalarial immunity. In contrast, in the advanced phase of the disease severe splenic disorder developed. The relative proportion of the T helper cell fraction decreased in all splenic compartments. The spleen was massively enlarged, loaded with malaria pigment and the marginal zone was progressively destroyed. In these conditions, the mice died from overwhelming parasitaemia and severe anaemia. The failure of the host response to control the *P. vinckei* infection could be due to direct or mediated cytotoxic effects of malaria antigens similar to those described for lipopolysaccharide (7, 14). Moreover, the observed splenic disorder coincided with the accumulation of malaria pigment, which is known to inhibit phagocytosis and the respiratory burst of macrophages (15). Pigment accumulation could therefore be a cause of the observed changes in the spleen.

Immunohistochemical examination of the liver during infection confirmed that large numbers of leukocytes were present within the sinusoids and as periportal infiltrates. The meaning of the portal tract infiltration, also observed by other authors (4), is not clear. The monocytes seen in the sinusoids may be destined to become Kupffer cells, which would act as phagocytes and antigen-presenting cells. The infiltrated T cells seen in the advanced phase of the disease may activate the liver macrophages and thereby potentiate their antimalarial capacity. Furthermore, the liver is known to accumulate pigment during malaria infection (1). Pigment in the resident Kupffer cells and in recently immigrated monocytes was already visible at a relatively low parasitaemia (5%). This indicates that the mononuclear phagocyte complex, at different stages of maturation, is responsible for phagocytosis of parasites and an important system contributing to parasite clearance from circulation.

Based on these observations, we conclude that the early phase of *P. vinckei* malaria in nonimmune mice is characterized by accumulation of T cells and activation of mononuclear phagocytes in the spleen and in the liver as an attempt of nonspecific inhibition of parasite growth and multiplication. In contrast, in the late phase of the disease, this protective cellular mechanism can not keep up with the rapidly multiplying parasites and the mice die with severe anaemia and hyperparasitaemia before adequate specific immunity can develop.

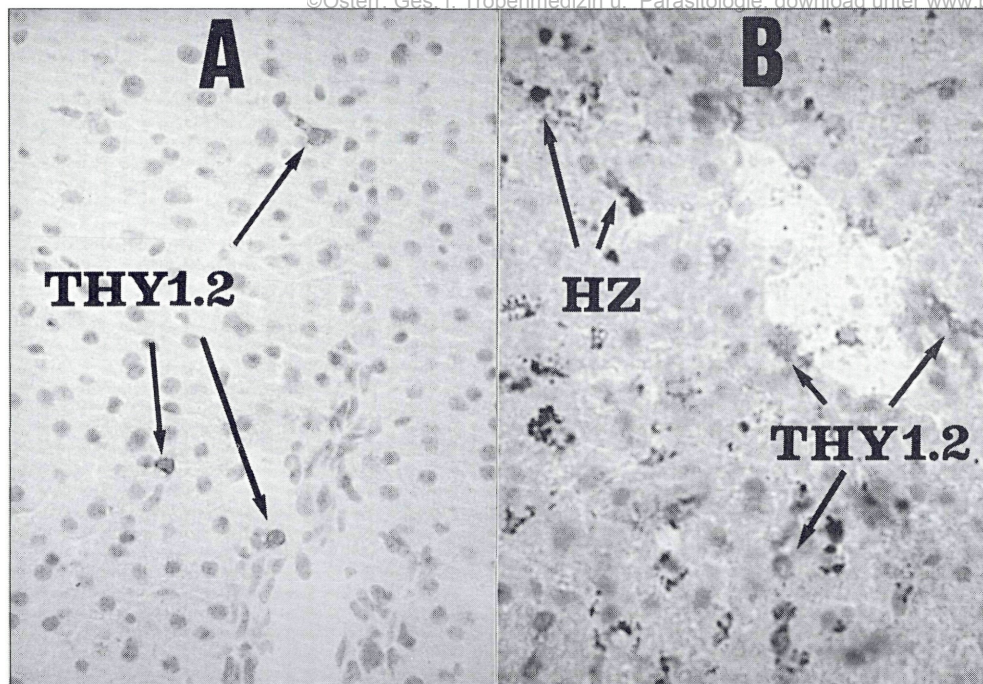


Figure 1:

Immunohistological patterns of Thyl.2+ lymphocytes in liver sections of Balb/c mice. A: without infection (control) and B: in the late phase of *P. vinckei* malaria (60% parasitaemia)<sup>1</sup>.

1) Arrows from Thyl.2 indicate representative Thyl.2+ cells showing a red colour as the result of the reaction using the substrate appropriate to alkaline phosphatase. Arrows from HZ indicate representative cells in the liver showing malaria pigment accumulation (haemozoin).

### Key words

Malaria, spleen, liver, immunohistochemistry, flow cytometry.

### Zusammenfassung

#### *T-Zellanreicherung in Milz und Leber während einer murinen Plasmodium vinckei Malaria*

Die T-Zellverteilung in der Milz und in der Leber von *Plasmodium vinckei* infizierten Balb/c Mäusen wurde mittels Immunhistologie und Durchflußzytometrie untersucht. In der Milz nehmen die absolute Zahl der T-Zellen und die CD4+ und CD8+ T-Zellfraktionen zu. In der frühen Phase der Erkrankung steigt der relative Anteil der CD4+ T-Zellen in der Marginalzone und in den Follikeln, die sich stetig vergrößern und in denen sich Keimzentren entwickeln. Im Gegensatz dazu sinkt der relative Anteil der CD4+ T-Zellen in allen Milzkompartimenten in der späten Phase der Erkrankung, in der auch die Marginalzone zerstört wird. Eine Akkumulation aller T-Zellfraktionen in der Portalzone und in den Sinusoiden der Leber findet ebenfalls während der *P. vinckei* Malaria statt. Diese Untersuchungen zeigen eine frühe T-Zellreaktion in Milz und Leber, welche die Hyperparasitämie und den fatalen Ausgang der *P. vinckei* Malaria allerdings nicht verhindern kann.

### Schlüsselwörter

Malaria, Milz, Leber, Immunhistologie, Durchflußzytometrie.

### Acknowledgements

The authors are grateful to G. Sahlmüller and U. S. Sehmsdorf for technical assistance, and to M. Ferreira Chaves, S. Bantz and R. Rudolph for help and comments.

### Summary

Spleen and liver of *Plasmodium vinckei* infected Balb/c mice were investigated by immunohistology and flow cytometry. In the spleen, the absolute number of T cells was found to increase, including CD4+ and CD8+ cell fractions. In the early phase of the disease, the CD4+ T cells showed a considerable accumulation in the marginal zone and in the follicles, which progressively enlarged and developed germinal centres. In contrast, in the late phase of the disease, the CD4+ T cells decreased in all the compartments and the marginal zone became destroyed. An accumulation of all T cell fractions was also observed in the portal zone and in the sinusoids of the liver. These results show an early T cell response in the spleen and in the liver, which, however, is not able to prevent overwhelming parasitaemia and the fatal outcome of *P. vinckei* malaria.

## References

1. ARESE, P., TURRINI, F., GINSBURG, H. (1991):  
Erythrophagocytosis in malaria: Host defence or menace to the macrophage?  
*Parasitol. Today* 7, 25-28.
2. CLARK, I. A., ALLISON, A. C. (1974):  
*Babesia microti* and *Plasmodium berghei* infections in nude mice.  
*Nature* 252, 328-329.
3. CLARK, I. A., HUNT, N. H. (1983):  
Evidence for reactive oxygen intermediates causing hemolysis and parasite death in malaria.  
*Infect. Immun.* 39, 1-6.
4. DOCKRELL, H. M., DE SOUZA, J. B., PLAYFAIR, J. H. L. (1980):  
The role of the liver in immunity to blood stage malaria.  
*Immunol.* 41, 421-430.
5. ERMAK, T. H., STEGER, H. J., WOFSY, D. (1989):  
Treatment of murine lupus with monoclonal antibody to L3T4.  
*Lab. Invest.* 61, 447-456.
6. FINNEMANN, S. et al. (1992):  
Antibody response in *Plasmodium vinckei* malaria after treatment with chloroquine and adjuvant interferon-gamma.  
*Parasitol. Res.* 78, 629-634.
7. KREMSNER, P. G., NEIFER, S., FERREIRA-CHAVES, M., RUDOLPH, R., BIENZLE, U. (1992):  
Interferon-gamma induced lethality in the late phase of *Plasmodium vinckei* malaria despite effective parasite clearance by chloroquine.  
*Eur. J. Immunol.* 22, 2873-2878.
8. KUMAR, S., GOOD, M. F., DONTFRAID, F., VINETZ, J. M., MILLER, L. H. (1989):  
Interdependence of CD4 + T cells and malaria spleen in immunity to *Plasmodium vinckei vinckei*.  
*J. Immunol.* 143, 2017-2023.
9. LEE, S., CROKER, P., GORDON, S. (1986):  
Macrophage plasma membrane and secretory properties in murine malaria.  
*J. Exp. Med.* 163, 54-74.
10. LOOAREESUWAN, S. et al. (1987):  
Dynamic alterations in splenic function during acute *Plasmodium falciparum* malaria.  
*N. Engl. J. Med.* 317, 675-679.
11. NEIFER, S. et al. (1991):  
Interferon-gamma treatment in mice experimentally infected with *Trichinella spiralis*.  
*Parasitol. Research* 77, 437-442.
12. PRADA, J. et al. (1994):  
Splenic interleukin 1 gene expression is associated with accumulation of macrophages and oxygen radical production in *Plasmodium vinckei* malaria.  
*J. Pathol.* 173, in press.
13. SHEAR, H. L., NUSSENZWEIG, R. S., BIANCO, C. (1979):  
Immune phagocytosis in murine malaria.  
*J. Exp. Med.* 149, 1288-1298.
14. STEVENSON, M. M., KRAAL, G. (1989):  
Histological changes in the spleen and liver of C57B1/6 and A/J mice during *Plasmodium chabaudi* AS infection.  
*Exp. Mol. Pathol.* 51, 80-95.
15. TURRINI, F., SCHWARZER, E., ARESE, P. (1993):  
The involvement of hemozoin toxicity in depression of cellular immunity.  
*Parasitol. Today* 9, 297-300.
16. WEISS, L., GEDULDIG, U., WEIDANZ, W. (1986):  
Mechanisms of splenic control of murine malaria: reticular activation and the development of a blood-spleen barrier.  
*Am. J. Anat.* 176, 251-285.

**Korrespondenzadresse:** Univ. Doz. Dr. Peter G. Kremsner  
Institut für Tropenmedizin  
Engeldamm 62  
D-10179 Berlin · Bundesrepublik Deutschland

# ZOBODAT - [www.zobodat.at](http://www.zobodat.at)

Zoologisch-Botanische Datenbank/Zoological-Botanical Database

Digitale Literatur/Digital Literature

Zeitschrift/Journal: [Mitteilungen der Österreichischen Gesellschaft für Tropenmedizin und Parasitologie](#)

Jahr/Year: 1994

Band/Volume: [16](#)

Autor(en)/Author(s): Neifer S., Prada J., Bienzle U., Kremsner Peter Gottfried

Artikel/Article: [T cell accumulation in spleen and liver during murine Plasmodium vinckei malaria. 93-98](#)