© Biodiversity Heritage Library, http://www.biodiversitylibrary.org/

# Histological Observations on the Ovary, Oviduct and Uterus of the Naked-Mole-Rat

By F. I. B. Kayanja and J. Jarvis[1]

*Department of Veterinary Anatomy and Histology and Department of Zoology, University of Nairobi*

*Eingang des Ms. 12. 12. 1970*

## Introduction

The naked mole-rat *Heterocephalus glaber* (Ruppell), is a small, practically hairless rodent which belongs to the family Bathyergidae. It is found in hot dry regions of Kenya, Ethiopia and Somalia. It reaches a maximum weight of 80 g but animals exceeding 30 g appear to be adult. *Heterocephalus* is completely fossorial and lives in colonies of as many as 100 individuals; they dig an intricate and extensive system of burrows.

The harsh semi-desert condition in which these animals live and the fact that rainfall is erratic and may fail completely in some years (Jarvis 1969), probably affects both litter size and the breeding season in *Heterocephalus*. In years where the rainfall is poor, mortality of young would be high and it is possible that breeding is also curtailed. In good years, a relatively high litter size (compared with other East African mole-rats) would be advantageous in maintaining the numbers in the colony and making up losses incurred in the poor years.

At present, little information is available on the time and duration of the breeding season and litter size of these mole-rats.

Data on animals from Mtito Andei, Kenya (Jarvis 1969) suggest that here *Heterocephalus* breeds between February and April, a period which coincides with the long rains. The only record of litter size is from one litter of five born in captivity. Pregnant females have not been caught in the field so far. Observations on the captive animal suggest that pregnant *Heterocephalus* remain in or near the nest area and are therefore difficult to trap. Because of this, additional data obtained from *Heterocephalus* in estrus provide a valuable contribution to our limited knowledge of the reproductive biology of these animals.

Mossman (1966) stressed the fact that most of our knowledge gained from the study of rodent ovarian biology can be widely applied to other mammals. He believed that such knowledge represents a "common denominator" of mammalian reproductive structure and function.

## Materials and Methods

The ovaries, oviduct and uterus were taken from three naked mole-rats believed to be in estrus. One of the three animals was a captive individual. The specimens were fixed in Bouin's fluid and the 8 μ Paraffin sections were stained with Haematoxylin

[1] Present address: Department of Anatomy, Columbia Medical School, U.S.A.

Z. Säugetierkunde 36 (1971) 114—121
© 1971 Verlag Paul Parey, Hamburg und Berlin

© Biodiversity Heritage Library, http://www.biodiversitylibrary.org/


and Eosin, Heidenhain's Azan and Van Gieson techniques. The ovaries were serially sectioned.

Three more naked mole-rats weighing 22, 45 and 50 grammes, were obtained during January 1970 and were used for dissection, morphological studies of the female reproductive organs as well as histological investigations.

## Observations

Three animals were considered to be in estrus because the vulva was destended, the vagina perforate and the mammary glands enlarged. In the captive animal, courtship and mating behaviour had also been observed.

The oviduct and especially the uterus from the three animals believed to be in estrus were turgid and extremely vascular. Prominent vessels from the mesometrium formed loops at right angles to the longitudinal axis of the uterus and passing towards its antimesometrial side where they frequently formed anastomoses. In contrast, the reproductive organs from the three naked mole-rats obtained during January 1970 were smaller and very much less vascular.

## The Ovary

The ovaries measured about 5×2.5×1 mm and were somewhat flattened dorsoventrally. They were found immediately caudal or caudo-lateral to the kidneys (Fig. 1). The left kidney was always more caudal in position than the right one and the left ovary was found along the caudo-lateral border of the left kidney.

The ovaries were covered by a principally cuboidal germinal epithelium varying in height between 3.0 to 5.0 μ. A distinct tunica albuginea lay below the germinal epithelium (Figs. 2 and 3). The former was uneven in thickness but on the average was 90 μ deep, although in a few isolated regions, it was over 150 μ in thickness. Collagenous fibres arranged in a three dimensional system, mainly parallel to the ovarian surface, were easily identified within the tunica albuginea.

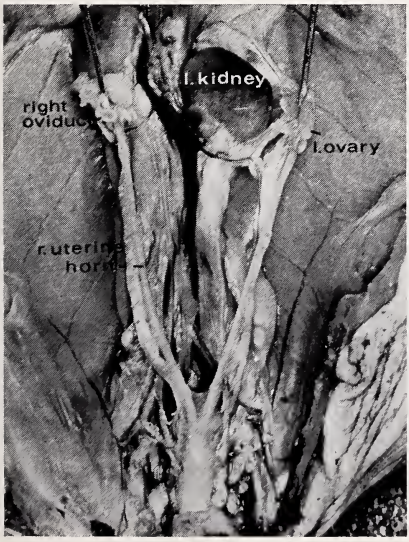


### The Ovary during estrus

A zona parenchymatosa was present beneath the tunica albuginea which was incompletely divided into two regions. The outermost region contained many primordial follicles most of which were surrounded by an obvious epithelium of highly attenuated cells. The smallest egg-cells measured 18.5 μ while their nuclei were 10.0 μ in diameter. These primordial follicles formed prominent egg-nests in the outer region of the zona parenchymatosa (Fig. 4) and sometimes continued into the base of the mesovarium.

*Fig. 1.* A ventral view of the female reproductive organs of the naked mole-rat (anestrus). The right ovary has been reflected to expose the oviduct and the left ovary is slightly displaced laterally. X 3.

© Biodiversity Heritage Library, http://www.biodiversitylibrary.org/



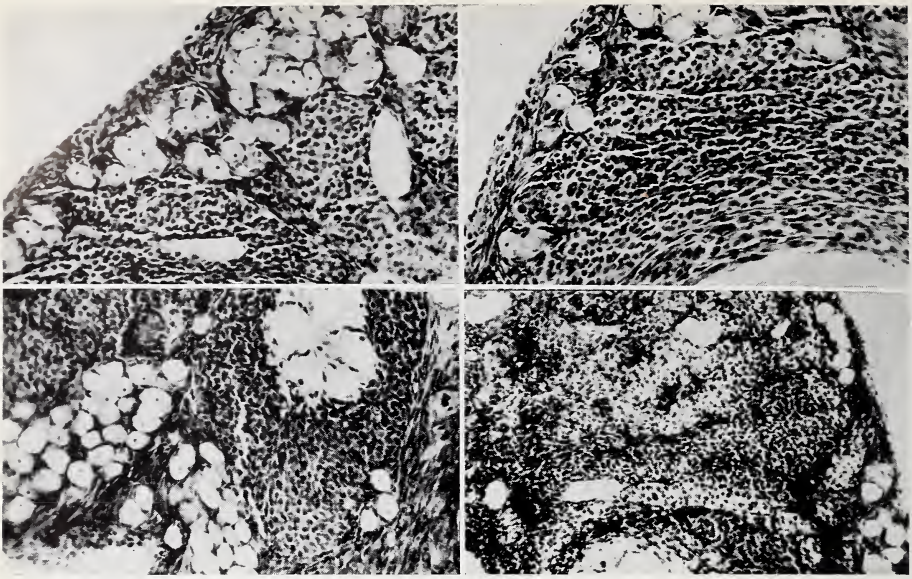

*Fig. 2 (above l.).* A section through the zona parenchymatosa of the ovary during estrus showing the germinal epithelium, tunica albuginea, nests of primordial follicles and the interstitial gland tissue. X 310 H. Azan. — *Fig. 3 (above r.).* A section through the zona parenchymatosa showing the tunica albuginea, primordial follicles and interstitial gland tissue during estrus. Portion of an atretic tertiary follicle is also shown. X 310 H. Azan. — *Fig. 4 (below l.).* A section through the zona parenchymatosa showing the primordial follicles and interstitial gland tissue during estrus X 310 H. Azan. — *Fig. 5 (below r.).* A section through the ovarian cortex showing the interstitial tissue in the deepest portions of the zona parenchymatosa during estrus. Note the stromal fibroblast lamellae dividing the interstitial gland tissue into masses of unequal size. X 150 H. Azan.

Compared to the primordial follicles, the primary follicles with a cuboidal or columnar epithelium covering, were fewer in number. They were also found in the outer region of the ovarian cortex but usually lay deeper to the primordial follicles. The primary follicles measured from 20 to 70 μ in diameter. The secondary follicles with a multilayered epithelial covering measured from 50 to just over 100 μ in diameter. The oocyte measured 30 μ when the secondary follicles were 75 μ in diameter. The secondary follicles also frequently lay deeper to the primordial follicles and often extended into the inner region of the zona.

The antrum of the tertiary follicles started to develop when they were 130 μ in diameter and was well established in the 190 μ diameter tertiary follicles. In the latter, the oocyte measured about 75 μ in diameter. In tertiary follicles with an established antrum, the thecal coat, especially the theca interna, was well developed. Thus in *Heterocephalus*, the antrum developed when the follicles were between 130 to 190 μ in diameter. This conforms with the suggestion bei Harrison (1962) that the antrum develops after the first phase of follicular growth is completed which in small mammals, occurs when the follicle is between 150 to 200 μ in diameter.

Few tertiary follicles from 500 to 1000 μ in diameter were seen. The number of these large follicles, naturally was smaller than that of the primary and secondary follicles. In one ovary 12 large tertiary follicles were present, several of which were atretic and less than 700 μ in diameter. In tertiary follicles of this size, the theca interna was frequently more prominent than both the membrane granulosa and the theca externa. In the captive naked mole-rat three tertiary follicles believed to be

© Biodiversity Heritage Library, http://www.biodiversitylibrary.org/


pre-ovulatory were found in one ovary. The second ovary from the same animal contained only one pre-ovulatory follicle. In one naked mole-rat obtained from the field, one ovary contained four pre-ovulatory follicles while the other had only two such follicles. In the other animal captured from the field each ovary contained three pre-ovulatory follicles. All follicles classified as pre-ovulatory, were anchored into the ovarian surface and the tunica albuginea along the contact region was of minimal thickness.

The inner region of the zona parenchymatosa was mainly composed of remarkable accumulations of interstitial gland tissue (Figs. 2, 4 and 5). The centre of these cellular masses, in some instances, still contained the products of the degenerating ovum within the remains of the antrum of atretic follicles. The interstitial gland tissue was subdivided into masses of varying size by thin septa of stromal tissue (Fig. 5). Occasionally groups of primordial, single primary, secondary and tertiary follicles were encountered in the septa of stromal fibroblasts. The interstitial gland tissue cells resembled the theca interna cells of the tertiary follicles except that the former were deeper staining and less well organised in their arrangement.

The centre of the ovary contained a well developed and distinct zona vasculosa. It contained many blood vessels which were continuous with those of the mesovarium. Isolated and insignificant cell groups resembling the interstitial gland tissue were occasionally seen within the mesovarium.

### The Ovary during anestrus

The ovaries were smaller in size and the most conspicuous observation was the predominance of primordial and primary follicles in the zona parenchymatosa (Figs. 6 and 7). The interstitial gland tissue was relatively less well developed compared to that seen during estrus (Figs. 2, 3, 5 and 7). Some secondary follicles of about 55 μ diameter were encountered together with a few atretic tertiary follicles of about 135 μ diameter. No tertiary follicles of more than 140 μ diameter were found in the ovaries during anestrus.

## The Oviduct

The oviduct was suspended by a short thin mesosalpinx. Although the bursa ovarica was not extensive, the fimbriae formed elaborate processes about 1—2 mm in length in most cases lying cranio-lateral to the ovary. The infundibulum was short while the isthmus portion of the oviduct was coiled and mainly lay dorso-lateral to the ovary (Fig. 1).

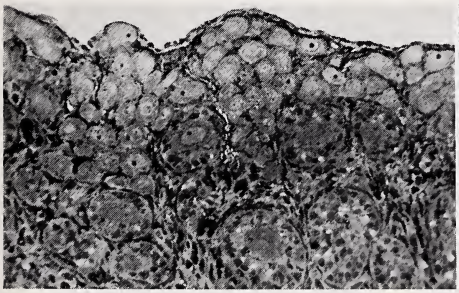

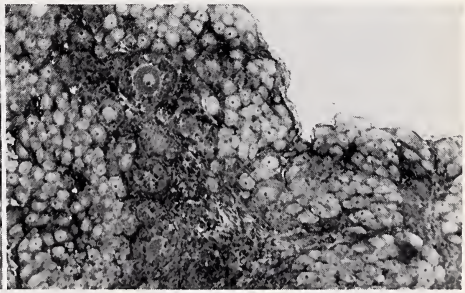

*Fig. 6 (left).* A section through the zona parenchymatosa from an ovary in anestrus. X 310 Toluidine blue. — *Fig. 7 (right).* A section through the zona parenchymatosa from an ovary in anestrus. X 150 Toluidine blue.

© Biodiversity Heritage Library, http://www.biodiversitylibrary.org/

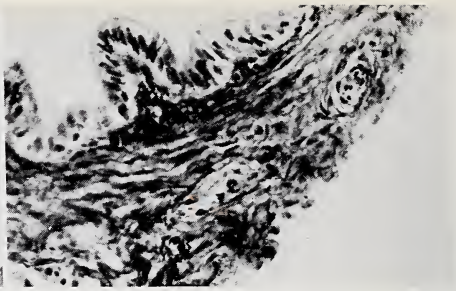

*Fig. 8 (left).* A cross-section through the isthmus portion of the oviduct during estrus X 150 H. Azan. — *Fig. 9 (right).* A cross-section through part of the isthmus of the oviduct during estrus. Note the blood vessels in the ill-defined lamina vascularis. X 310 H. Azan.

The wall of the oviduct was composed of a tunica mucosa, tunica muscularis and tunica serosa (Figs. 8 and 9). At estrus the tunica mucosa carried a high columnar epithelium measuring about 20 μ on the fimbriae and 16.0 μ in height in the isthmus portion. As well as being heighest on the fimbriae, the epithelium here also displayed better developed cilia (Fig. 10). As in the domestic mammals, the lamina propria formed the core of the longitudinal folds of the tunica mucosa. The lamina propria was richly vascularised, especially in the fimbriae.

During anestrus the epithelium covering the fimbriae measured only about 15 μ in height. The cilia were still well developed and conspicuous while the lamina propria was poorly vascularised. Towards the exterior of the oviduct was a distinct tunica muscularis composed principally of smooth muscle fibres with a circular arrangement although many oblique muscle fibres were also seen within this layer. Beyond the tunica muscularis and towards the periphery was the tunica serosa, which was composed of a connective tissue layer with many collagenous fibres and a covering layer of an attenuated epithelium of simple squamous cells. A few longitudinal arranged smooth muscle fibres were identified within the tunica serosa. They were most prominent where the oviduct was suspended by the mesosalpinx. Blood vellels were also occasionally seen in the tunica serosa forming a poorly developed lamina vascularis (Fig. 9).

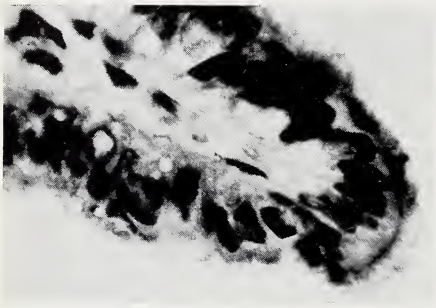

*Fig. 10.* A section through the tip of a longitudinal mucosal fold of the infundibular portion of the oviduct during estrus. Note the prominent cilia. X 1,250 H. Azan.

## The Uterus

The uterus was composed of two horns passing from the region of the kidneys and converging caudally to join the vagina (Fig. 1). The uterus was about 2—3 cm in length. Each horn was a long thin tube suspended by a thin transparent mesometrium. Along the attachment an elongated strip of adipose tissue about one millimetre in width was consistently observed (Fig. 1).

The uterus was composed of a tunica mucosa (endometrium), a tunica muscularis

© Biodiversity Heritage Library, http://www.biodiversitylibrary.org/


(myometrium), a lamina vascularis and the tunica serosa (Fig. 11).

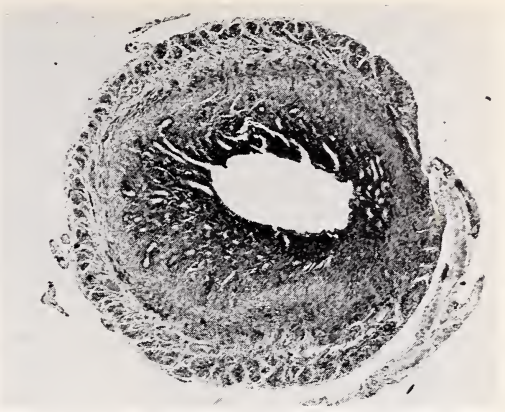

*Fig. 11.* A cross-section through the uterine horn showing the tunica mucosa, tunica muscularis and tunica serosa during estrus. X 25 H & E.

### The Uterus during estrus

The tunica mucosa carried a simple columnar epithelium of about 16.0 μ height (Fig. 12). The epithelium was lowest along the antimesometrial side of the uterine lumen. The lamina propria was divisible into two regions. The layer nearest to the epithelium was more cellular but less fibrous than the layer nearest to the tunica muscularis. Slight edema was found within the cellular superficial zone which was also richly vascularised (Fig. 13). The connective tissue found in this region were mainly fibroblasts, although some lymphocytes and plasma cells were also identified.

The uterine glands, situated within the lamina propria, formed simple, relatively straight tubes extending towards the tunica muscularis and opening along the uterine surface (Fig. 14). The lumina of the glandular tubules were distended. Occasionally the glands slightly coiled as they approached the tunica muscularis.

The tunica muscularis was principally composed of smooth muscle fibres with a circular arrangement. This layer was best developed at the mesometrial side and was thinner or often broken up into bundles by connective tissue along the antimesometrial side of the uterus. Peripherally the tunica muscularis was bound by a connective tissue layer with many blood vessels. From this lamina vascularis, blood vessels pierced the tunica muscularis to enter the endometrium.

Towards the periphery was the tunica serosa the innermost layer of which was made up of a lamina muscularis serosae. The latter was composed of longitudinally arranged smooth muscle fibres forming bundles which extended into the mesometrium.

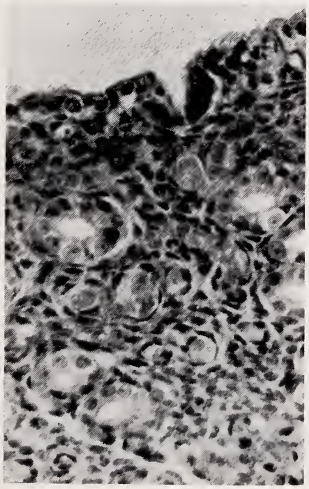

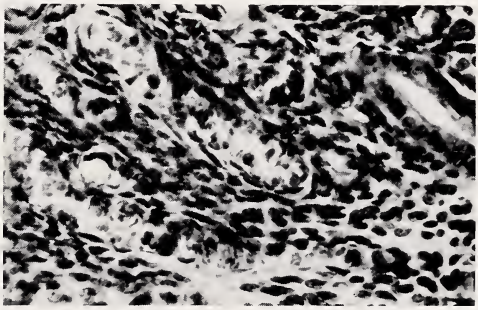

*Fig. 12 (left).* A section through the endometrium showing the uterine epithelium and the vascular lamina propria during estrus. X 500 Van Gieson — *Fig. 13 (above).* A section through the vascular lamina propria during estrus. X 500 H. Azan.

© Biodiversity Heritage Library, http://www.biodiversitylibrary.org/


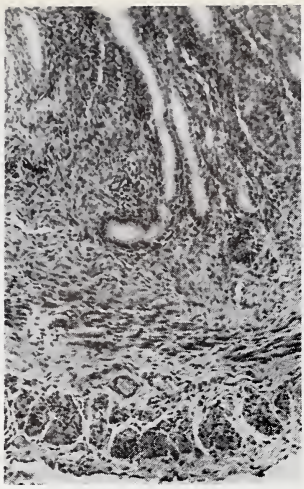

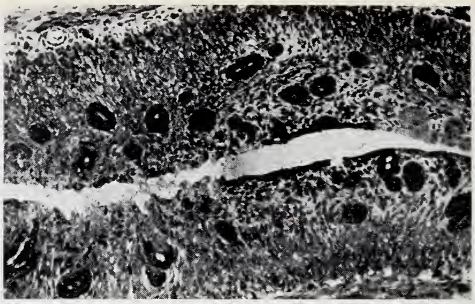

*Fig. 14 (left).* A section through the uterine wall showing the tubular glands in the endometrium, the myometrium, lamina vascularis and the tunica serosa during estrus. The longitudinal muscle fibre bundles in the tunica serosa are well shown. X 150 H & E — *Fig. 15 (above).* A longitudinal section through the uterus during anestrus. X 150 Toluidine blue.

The outermost layer was made up of connective tissue containing many collagenous fibres and covered by an attenuated simple squamous epithelium.

### The Uterus during anestrus

The uterine epithelium was cuboidal to low columnar and measured between 8 and 10 μ in height. The uterine glands appeared shorter than at estrus but were somewhat flask-shaped. No edema was observed within the lamina propria (Fig. 15).

## Discussion

The ovary, oviduct and uterus of the naked mole-rat have the characteristic histological structure already described in other mammals. The ovary conforms to the general pattern of the rodent ovary as described by Mossman (1966). In the naked mole-rat the ovary contains many follicles mainly of small size and follicular atresia is evident prior to ovulation. Only a few follicles of ovulatory size were present together with significant amounts of interstitiall gland tissue. The observation that during estrus the ovaries contained between four and six pre-ovulatory follicles is consistent with the litter size record given by Jarvis (1969). More investigations are necessary before it can be decided whether the litter size varies with the environmental conditions.

As Mossman (1966) suggested, the amount of interstitial gland tissue is variable in the different rodent species. Only a small insignificant proportion of interstitial gland tissue was identified in the mesovarium. In this species the interstitial gland tissue masses within the zona parenchymatosa were clearly of atretic follicle origin. During anestrus when there were only a few atretic tertiary follicles, the interstitial gland tissue was less well developed.

Prior to ovulation, the oviduct epithelium is high columnar with well developed cilia. The latter as well as increased vascularisation of the lamina propria, are most pronounced in the fimbriae. Bloom and Fawcett (1968) stated that the oviduct epithelium was highest in the ampulla and diminuished towards the uterus. This observation is distinct in the naked mole-rat oviduct. Bloom and Fawcett (1968) also

© Biodiversity Heritage Library, http://www.biodiversitylibrary.org/


suggested that the increased vascularity of the lamina propria gives the fimbriae the enlargement and turgidity which are functionally significant in capturing the ova. The presence of oblique smooth muscle fibres within the tunica muscularis of the naked mole-rat oviduct indicates that the musculature is probably arranged in spiral forms as recorded by SCHILLING (1962) in the sheep and cow.

The histological structure of the naked mole-rat uterus resembles that of the rat and guinea-pig. The uterine epithelium, however, is lower in height than that of the guinea-pig (LOEB 1914, STOCKARD and PAPANICOLAOU 1917) at estrus. At this stage, the uterine glands form straight tubes with distianct lumina as was also described in the guinea-pig by ECKSTEIN and ZUCKERMAN (1956).

## Acknowledgement

We are grateful to Professor R. R. HOFMANN and Dr. J. SALE for their advice, criticism and aid in obtaining the naked mole-rats. We are greatly indebted to Miss JASMAIL IHITE and Mr. E. NJOGU for technical assistance.

## Zusammenfassung

Die nackte Maulwurfsratte, *Heterocephalus glaber,* ist ein kleines, praktisch haarloses Nagetier aus der Familie der Bathyergidae. Es existiert unter rauhen Halbwüsten-Bedingungen. Die Morphologie und mikroskopische Anlage des Ovarium, des Eileiters und des Uterus wurden während der Östrus- und Anöstrus-Periode untersucht und beschrieben. Prä-ovulatorische Follikel wurden während der Östrus-Periode gezählt, und ihre Gesamtzahl wurde als Anhaltspunkt für die Wurfgröße verwendet. Die Menge des interstitiellen Drüsengewebes steht in Beziehung zu der Zahl der atretischen Follikel.

## Summary

The naked mole-rat *Heterocephalus glaber,* is a small practically hairless rodent which belongs to the family Bathyergidae. This animal lives in a harsh semi-desert environment. The morphology and microarchitecture of the ovary, oviduct and uterus were studied during estrus and anestrus. Pre-ovulatory follicles were counted during estrus and the total number used as an indication of litter size. The amount of interstitial gland tissue is related to the number of atretic follicles.

## References

BLOOM, W., and FAWCETT, Don. W. (1968): A textbook of Histology, W. B. Saunders Company, Philadelphia — London — Toronto.

ECKSTEIN, P., and ZUCKERMAN, S. (1956): Changes in the accessory reproductive organs of the nonpregnant female. In Marshall's Physiology of Reproduction. Vol. 1. Part One. Ch. 6. 3rd Edition by A. S. Parkes. Longmans London.

HARRISON, R. J. (1962): The structure of the ovary. In: The Ovary. Edited by S. Zuckerman, A. M. Mandl and P. Eckstein. London Academic Press.

JARVIS, J. U. M. (1969): The breeding season and litter size of African Mole-rats. J. Reprod. Fert. Suppl. **6**, 237.

LOEB, L. (1914): The correlation between the cyclic changes in the uterus and ovaries in the guinea-pig. Biol. Bull. **27**, 1.

MOSSMAN, H. W. (1966): The Rodent Ovary. Symp. Zool. Soc. **15**, 455.

SCHILLING, E. (1962): Untersuchungen über den Bau und die Arbeitsweise des Eileiters von Schaf und Rind. Zbl. Veterinar Med. **9**, 805.

STOCKARD, C. R., and PAPANICOLAOU, G. N. (1917): The existence of a typical oestrus cycle in the guinea-pig — with a study on its histological and physiological changes. Amer. J. Anat. **22**, 225.

*Authors addresses:* F. I. B. KAYANJA and J. JARVIS, University of Nairobi, Kenia, P. O. Box 30197, Department of Veterinary Anatomy and Histology

# ZOBODAT - www.zobodat.at

Zoologisch-Botanische Datenbank/Zoological-Botanical Database

Digitale Literatur/Digital Literature

Zeitschrift/Journal: Mammalian Biology (früher Zeitschrift für Säugetierkunde)

Jahr/Year: 1970

Band/Volume: 36

Autor(en)/Author(s): Kayanja F.I.B., Jarvis J. U. M.

Artikel/Article: Histological Observations on the Ovary, Oviduct and Uterus of the Naked-Mole-Rat 114-121