

# Biology of the rice rat (*Oryzomys palustris natator*) in a laboratory environment

## II. General skull morphology

By A. WALLACE PARK, MARY BENSTEAD and B. J. A. NOWOSIELSKI-SLEPOWRON

*Departments of Dental Surgery, Medical Art and Biological Sciences, University of Dundee*

*Receipt of Ms. 29. 6. 1972*

### Introduction

The rice rats of the genus *Oryzomys* form part of the muroid subfamily Cricetinae which includes approximately 60 groups currently accepted as having generic status. Taxonomic studies by ELLERMAN (1941) and RINKER (1954) have accepted 57 of these groups as being valid genera and there is enough evidence to warrant full generic status for the remaining groups.

Various taxonomists have endeavoured to bring order into the complex inter-relationships of the cricetine genera but, in spite of their efforts, confusion still exists and is regarded by RINKER (1954) as being partially due to the reliance placed by workers on what is an inadequate set of characters, and on the failure to make allowances for the phenomenon of convergent evolution which usually exhibits its most striking changes in the dentition.

The immense task of clarifying the inter-relationships within the Cricetinae has not moved far beyond the point reached by ELLERMAN (1941) apart from extensive work on the neotropical phyllotine group by HERSHKOVITZ (1944, 1955, 1960, 1962, 1966) and little can be added to his original comments although they are some 30 years old.

In the present survey, we are dealing with an inbred feral strain of rice-rat (*Oryzomys palustris natator*) whose introduction to a laboratory environment has already been reported (PARK, NOWOSIELSKI-SLEPOWRON 1972). The fact that ELLERMAN (1941) has shown cranial characteristics to be of no use in arranging a key to cover the Cricetinae since all are more or less generalized Muridae and there are few characteristics that cannot be duplicated in any of the large genera, means that we must approach the present interpretation of the skull with caution.

Basic description of *Oryzomys* characteristics — both general and skull — stems from the observations of MERRIAM (1901) and GOLDMAN (1918) although the original description was made by CHAPMAN (1893) in relation to *O. palustris natator*. One account of *Oryzomys palustris natator* skull morphology is included in MERRIAM's (1901) observations and is based on a small number of specimens. MERRIAM stated that „ . . . skull large and massive, elongated, flattened on top, with strongly projecting everted superciliary ridges, which greatly increase the breadth across the orbits posteriorly, zygomata moderately spreading; palatal slits large and open. Compared with *Oryzomys palustris palustris* the skull is much larger and heavier, with broadly expanded supraorbital ridges and much larger and more broadly open incisive foramina“.

It is obvious from these comments that the description of the rice rat skull morphology encompasses a wide range of variation and that, in the present study, we

are unable to make any comparisons between *O. palustris palustris* and *O. palustris natator*. At the present time, the Dundee rice rat colony can be envisaged as approaching the state of an inbred strain, thus variations which may have arisen cannot be compared with original wild stock until specimens are available from such stock. Our aim, therefore, is to present an account of the skull morphology of rats of the Dundee colony to allow some comparison to be made with the well-documented albino laboratory rat (*Rattus norvegicus*).

The future use of the rice rat as a laboratory animal depends partly on the establishing of a standard of existing morphology and partly on the sequence of the growth pattern without which no experimental procedures can be contemplated.

## Material and methods

*Rat Selection:* The material used for this study was obtained from a 1-month series of rice rats (*Oryzomys palustris natator*) ranging from 1 to 16 months inclusive. Over 100 rats were used of which there were approximately equal numbers of male and females. Animals derived from a 24-hour series covering birth to 30 days were also examined but were excluded from the present observations on the proviso that morphological standard should be made on mature animals before coming involved with developmental changes.

*Specimen Preparation:* The rats were killed by an overdose of ether, various body measurements were made for future work and the heads were removed and immediately placed in a solution of 2% calcium acetate/10% formalin at a pH of approximately 7. Maceration of the skulls was first attempted by means of 1% KOH and a 30–45 minute period in an ultrasonic cleaner bath (SPENCE, TONKINSON 1969), and then application of acetone to degrease, and bleaching by means of 5% of 100 vols. H<sub>2</sub>O<sub>2</sub>.

This particular method, however, had the drawback that, the skulls of many of the younger animals tended to separate along the suture lines while undergoing the ultrasonic waves. As a result, we returned to a longer but non-disrupting method in which the specimen was immersed in 1% KOH for approximately 3–5 days before attempting to remove the superficial soft tissue, de-cerebrating, degreasing and bleaching.

*Nomenclature:* The use of the latinized veterinary nomenclature of ELLENBERGER and BAUM (1926) would have been a natural first choice since it is specifically adapted to four-footed animals. With, however, a tendency to leave many of the Latin names out and replace these, in the anatomy world, with the B.N.A. nomenclature (JAMIESON 1916) the nomenclature used is that of the Birmingham Revision (B.R.) of the B.N.A. (The Basle Anatomical Nomenclature) terminology.

## Observations

Within a survey of the cranio-facial morphological characteristics of the rice rat lies not only the topology of the skull as a whole, but also each bone its relationship with adjacent bones.

The rice rat skull consists of the same basic bone elements as are found in any rodent and can be tabulated as shown on page 105.

To introduce the general characteristics of rice rat skull morphology, standard views of the adult rice rat skulls have been drawn in detail. Examination of both male and female skulls within the sample aged 1–16 months revealed no significant sex difference apart from that of size, therefore the morphology has been presented in drawings of the adult male (Figs. 1, 2, 3, 4, 5, 6, 7).

## Discussion

The present intention is not to cover all the aspects of the bones and their inter-relationships but rather to introduce the general characteristics of rice rat skull topology

Birmingham Revision of B.N.A.	ELLENBERGER and BAUM	Birmingham Revision of B.N.A.	ELLENBERGER and BAUM
2 nasals	os nasale	2 parietals	os parietale
2 premaxillaries	os incisivum	1 occipital	os occipitale
2 maxillaries	os maxilla	1 interparietal	os interparietale
2 zygomas	os zygomaticum	2 squamosals	os squamosum
2 palatines	os palatinum	2 periotic capsules	os perioticum
1 vomer	os vomer	2 tympanic bullae	os tympanicum
2 lacrimals	os lacrimale	6 auditory ossicles (2-malleus, 2-incus, 2-stapes)	malleus, incus stapes
1 ethmoid	os ethmoidale	4 conchae (turbinates) dorsal concha, ventral concha)	conchae nasalis
2 frontals	os frontale	1 hyoid	os hyoideum
1 basisphenoid	os sphenoidale	2 mandibles	os mandibula
1 presphenoid	os sphenoidale orale		

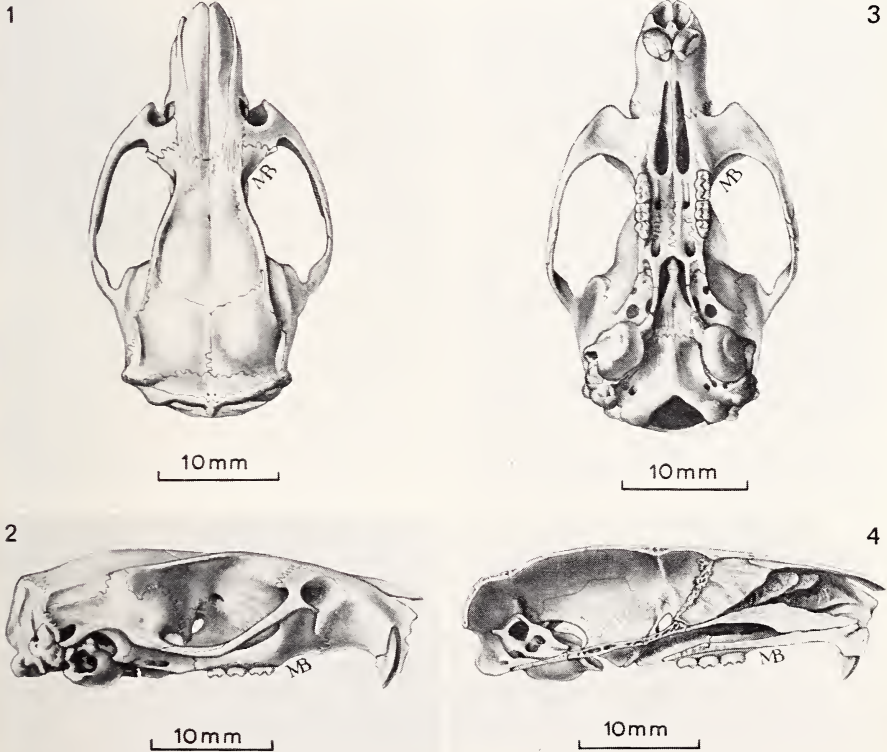


Fig. 1. Skull morphology of adult rat (*Oryzomys palustris natator*) dorsal aspect. — Fig. 2. Lateral aspect. — Fig. 3. Ventral (basal) aspect. — Fig. 4. Lateral aspect of a section taken through the median sagittal plane

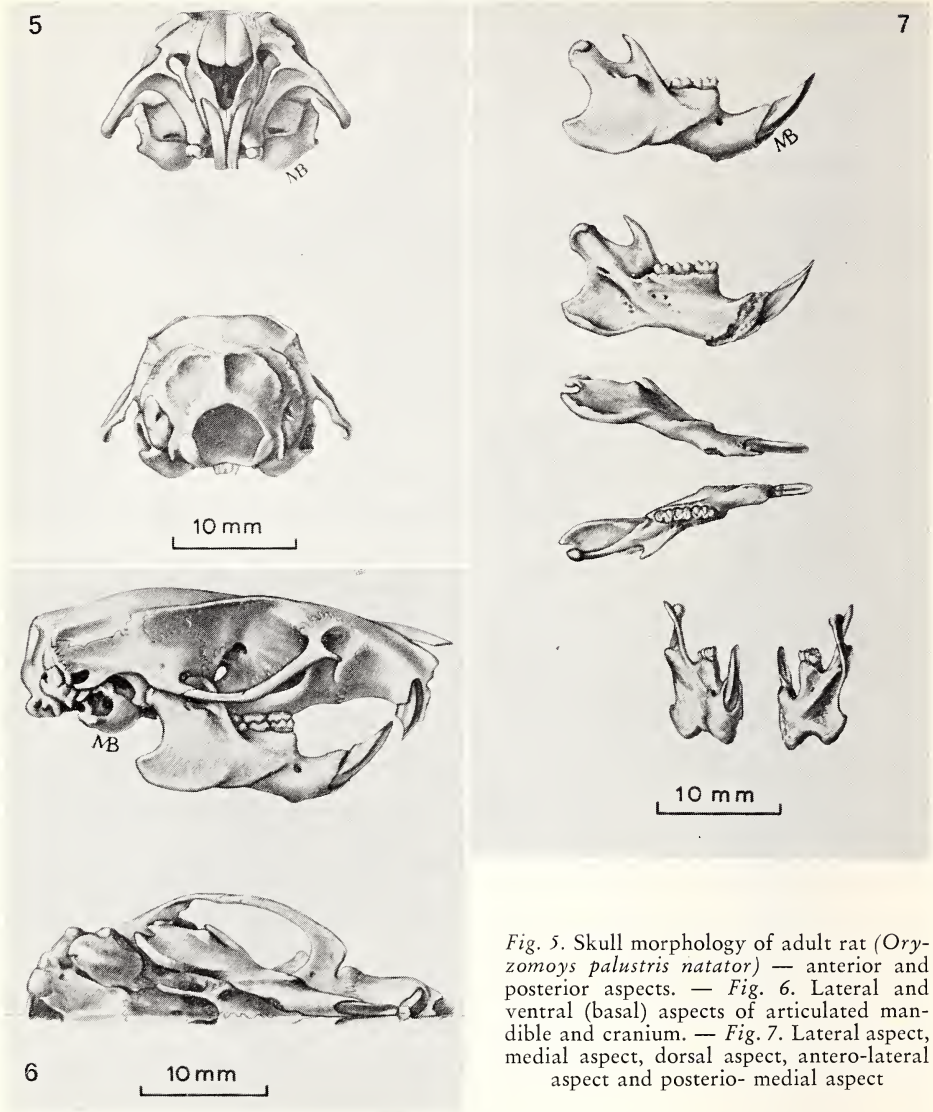


Fig. 5. Skull morphology of adult rat (*Oryzomys palustris natator*) — anterior and posterior aspects. — Fig. 6. Lateral and ventral (basal) aspects of articulated mandible and cranium. — Fig. 7. Lateral aspect, medial aspect, dorsal aspect, antero-lateral aspect and postero-medial aspect

and a number of simple comparisons with the albino laboratory rat (*Rattus norvegicus*). It is obvious that, except for its basic taxonomy, the rice rat has not been subjected to any extensive study apart from a comparative study of the hyoid apparatus (SPRAGUE 1941) and the much older descriptions of CHAPMAN (1893), MERRIAM (1901) and GOLDMAN (1918). As far as studies of the rice rat in a laboratory environment extend, apart from behavioral analysis — which does not concern us here — a little descriptive work has been undertaken by GUPTA and SHAW (1956) on tooth morphology and eruption, observations on aspects of genetics and development of fused molars (GRIFFITHS, SHAW 1961; SHAW, GRIFFITHS, OSTERHULTZ 1963; SOFAER, SHAW 1971), and on the presence of periodontal disease (GUPTA, SHAW 1955, 1956; GUPTA, AUSKAPS, SHAW 1957; SHAW, GRIFFITHS, AUSKAPS 1961; SHAW 1965 a and b, SHAW 1966; SHAW, KRUMINS 1966; SHAW, DICK 1966; DICK, SHAW 1966; DICK, SHAW,



SOCRANSKY 1968). Some work on the effect of protein-deficient diets on the bones of different genera of rat, including the rice rat, was reported by PACK and LUCAS (1971). The rice rats used in this work came from the daughter colony originally established by rats sent from the Dundee colony.

The general characteristics of the rice rat skull are more clearly shown in the drawings than in lengthy descriptions. On examination the skull is found to be fairly large, with flattening occurring over the dorsal region. The superciliary (supraorbital) ridges are definitely everted and projecting resulting in an increase in the breadth of the skull across the orbits posteriorly. In a similar way, the zygomatic complex shows a wide spreading while the anterior palatal foramina are long — reaching back to a line drawn at right angles to the foramina and joining the right and left first maxillary molar teeth. The frontal bones taper into a narrow point posteriorly in the median line between the parietal bones. The interparietal bone is small and its anterior border forms a straight line while a poorly defined median angle occurs posteriorly. The mandible has a broad angle and the coronoid process reaches above the level of the condylar process. It is proposed, at a later date, to publish a more detailed account of the individual bones forming the rice rat skull and of the dentition.

When attempting the description of the morphology of a particular rodent skull about which there is only a limited amount of known data, it is natural to try and attain perspective by using some baseline whereby comparisons can be demonstrated. To allow such comparison to be made, the well-documented albino laboratory rat (*Rattus norvegicus*) proved to be an excellent foil in previous work (PARK 1972) and has been used in the present work. When the skulls of these two species are compared several differences are revealed besides the more obvious one of size. The following list can only be regarded as a tentative one and used as a rough guide until further information on the variations are established.

1. The antero-posterior alignment of the maxillary and mandibular tooth rows is almost parallel in the rice rat whereas in the albino laboratory rat, greater curvature and a slight divergence posteriorly is shown.
2. The angulation of the mandibular molar teeth towards the median sagittal plane is more pronounced in the albino laboratory rat.
3. The anterior palatine foramina of the rice rat are much longer than those of the albino laboratory rat.
4. From both dorsal and ventral aspects, the squamosal bones of the rice rat as they curve laterally and anteriorly to meet the zygomatics, have small but definite notches medial to the zygomatic process.
5. The frontal bones of the rice rat taper into a narrow point posteriorly, in the median line between the parietal bones — along the coronal suture line. This particular suture junction is relatively straight in the albino laboratory rat.
6. The interparietal bone is very narrow in the rice rat, compared with the albino laboratory rat, and forms a relatively straight line along its anterior border. In the albino laboratory rat, the anterior border ends in a small notch or wedge.
7. In the mandible, the coronoid process is more vertically orientated in the rice rat and also more pointed. As a result of this the mandibular notch is deeper and wider than in the albino laboratory rat.
8. The angular process of the mandible of the rice rat is shorter and rounder, and does not extend so far posteriorly beyond the condylar process as it does in the albino laboratory rat.

#### Summary

General morphological characteristics of the skull of the recently introduced rice rat have been described following some 15 generations under laboratory conditions. Approximately

100 rats aged from 1—16 months were examined and a series of drawings made representing the more prominent skull characteristics, based on the male sample. For purposes of perspective, the skull of the albino laboratory rat (*Rattus norvegicus*) was used.

### Zusammenfassung

#### *Biologie der Reissratte (Oryzomys palustris natator) im Labor*

#### II. Allgemeine Schädelmorphologie

Es wurden allgemeine Schädelmerkmale von Reissratten beschrieben, die sich seit 15 Generationen unter Laborbedingungen befinden. Ungefähr 100 Ratten im Alter von 1—16 Monaten wurden untersucht; durch eine Serie von Zeichnungen wurden für die Männchen die auffallenden Schädelmerkmale herausgearbeitet. Als Grundlage der Beschreibung wurde der Schädel der Laborratte benutzt.

### Literature

- CHAPMAN, F. M. (1893): Description of a new subspecies of *Oryzomys* from the Gulf States. Bull. Am. Mus. Nat. Hist. V, 43—46.
- DICK, D. S.; SHAW, J. H. (1966): The infections and transmissible nature of the periodontal syndrome of the rice rat. Arch. oral Biol. II, 1095—1108.
- DICK, D. S.; SHAW, J. H.; SOCRANSKY, S. S. (1968): Further studies on the microbial agent or agents responsible for the periodontal syndrome in the rice rat. Arch. oral Biol. 13, 215—228.
- ELLENBERGER, W.; BAUM, H. (1926): Handbuch der vergleichenden Anatomie der Haustiere, 16th ed. Berlin: Julius Springer.
- ELLERMAN, J. R. (1941): The Families and Genera of Living Rodents, Vol. 1. British Museum (Nat. Hist.).
- GOLDMANN, E. A. (1918): The Rice of North America. North American Fauna No. 43. Washington Govt. Printing Office.
- GRIFFITHS, D.; SHAW, J. H. (1961): Fused molars and supernumerary molars in the rice rat. J. dent. Res. 40, 731—732.
- GUPTA, O. P.; SHAW, J. H. (1955): Periodontal disease in the rice rat II. Methods for evaluation of the extent of periodontal disease. O. Surg. O. Med. and O. Path. 9, 727—735.
- (1956): Periodontal disease in the rice rat. I. Anatomic and histopathologic findings. O. Surg. O. Med. and O. Path. 9, 592—603.
- GUPTA, O. P.; AUSKAPS, A. M.; SHAW, J. H. (1957): Periodontal diseases in the rice rat. IV. The effects of antibiotics on the incidence of periodontal lesions. O. Surg. O. Med. and O. Path. 10, 1169—1175.
- HERSHKOVITZ, P. (1944): A systematic review of the neotropical water rats of the genus *Nectomys* (Cricetinae). Univ. Mich. Museum Zool. Misc. Publ. No. 58, 1—88.
- (1955): South American marsh rats, genus *Holochilus*, with a summary of the sigmodont rodents. Fieldiana Zool. 37, 639—673.
- (1960): Mammals of Northern Colombia, preliminary report Nr. 8, Aboreal rice rats, a systematic revision of the subgenus *Oecomys*, genus *Oryzomys*. Proc. U. S. Nat. Museum 110, 513—568.
- (1962): Evolution of neotropical cricetine rodents (Muridae) with special reference to the phyllotine group. Fieldiana Zool. 46.
- (1966): South American swamp and fossorial rats of the Scaeteromyine group (Cricetinae, Muridae) with comments on the glans penis in murid taxonomy. Z. Säugetierkunde 31, 81—149.
- JAMIESON, E. B. (1916): The Basle Anatomical Nomenclature, B. N. A. London and Edinburgh: W. Green and Son Ltd.
- MERRIAM, C. H. (1901): Synopsis of the Rice Rat (Genus *Oryzomys*) of the United States and Mexico. Proc. Washington Acad. Sci. 3, 273—295.
- PACK, A. R. C.; LUCAS, R. B. (1971): The effect of protein deficient diets on the growth of the skull and long bones of different genera of rat. Int. Assoc. Dent. Res. (British Div.) abstract.
- PARK, A. W. (1972): Cranio-facial growth in post-natal development of a feral strain of rice rat (*Oryzomys palustris natator*). D.D.Sc. Thesis Univ. Dundee.
- PARK, A. W.; NOWOSIELSKI-SLEPOWRON, B. J. A. (1972): Biology of the rice rat (*Oryzomys palustris natator*) in a laboratory environment. Z. Säugetierkunde 37, 42—51.
- RINKER, G. C. (1954): The comparative myology of the mammalian genera *Sigmodon*, *Oryzomys*, *Neotoma* and *Peromyscus* (Cricetinae), with remarks on their intergeneric relationships. Univ. Michigan. Museum Zool. Miscel. Pub. No. 83, 124 pp.

- SHAW, J. H. (1965): Further studies on the sensitivity of the periodontal syndrome in the rice rat to dietary antibiotics. *J. dent. Res.* **44**, 431—438.
- (1965): Further studies on the use of nutritionally adequate diets for the production of the periodontal syndrome. *J. dent. Res.* **44**, 1278—1248.
- (1966): Influence of age on the periodontal syndrome in the rice rat. *Arch. oral Biol.* **11**, 1195—1197.
- SHAW, J. H.; GRIFFITHS, D.; AUSKAPS, A. M. (1961): The influence of antibiotics on the periodontal syndrome of the rice rat. *J. dent. Res.* **40**, 511—519.
- SHAW, J. H.; GRIFFITHS, D.; OSTERHULTZ, M. (1963): Relationship between body weight and occurrence of the fused molar and supernumerary molar traits in the rice rat. *Arch. oral Biol.* **8**, 777—778.
- SHAW, J. H.; KRUMINS, I. (1966): Mastication, submandibular gland enlargement and the periodontal syndrome in the rice rat. *Arch. Biol.* **11**, 279—291.
- SHAW, J. H.; DICK, D. S. (1966): Influence of route of administration of penicillin on periodontal syndrome in the rice rat. *Arch. oral Biol.* **11**, 369—371.
- SOFAER, J. A.; SHAW, J. H. (1971): The genetics and development of fused and supernumerary molars in the rice rat. *J. Embryol. exp. Morph.* **26**, 99—109.
- SPENCE, T. F.; TONKINSON, T. (1969): Application of ultrasonic cleaning in osteological studies. *J. Sci. Technol.* **15**, 47—50.
- SPRAGUE, J. M. (1941): A study of the hyoid apparatus of the Cricetinae. *J. Mammal.* **22**, 286—310.

*Authors' addresses:* A. WALLACE PARK, Department of Dental Surgery, Dental School, MARY BENSTEAD, Department of Medical Art, and Dr. B. J. A. NOWOSIELSKI-SLEPOWRON, Department of Biological Sciences, University of Dundee, Dundee, Scotland

## On functional fusions in footbones of Ungulates

By J. J. M. LEINDERS and P. Y. SONDAAR

*Receipt of Ms. 28. 5. 1973*

### Introduction

During evolution, especially in the Orders Artiodactyla and Perissodactyla we find a reduction of number of footbones, elongation of the metapodials and phalanges and sometime fusions of bones.

Those changes can be explained functionally: to provide the animal with a locomotion which is more efficient in running. Usually the tibia and fibula, radius and ulna fuse tightly together, which restricts the lateral movement and the motion is confined to the sagittal plane. In the ruminantia we find also the metapodials of the third and the fourth digit joined into one cannon bone. Some of the carpals and tarsals fuse also like navicular and cuboid, trapezoid and magnum, giving the carpal and tarsal joints more strength to lateral movements.

The fusions cannot be followed step by step due to fact that the fossil record is not complete. Probably the changes, or in other words the selection of the genetically fixed favourable fusions, take place in a rather short period.

The purpose of this paper is to describe some less common fusions in Perissodactyla and Artiodactyla and further to attempt to give a functional analysis, and the evolutionary meaning of those fusions.

# ZOBODAT - [www.zobodat.at](http://www.zobodat.at)

Zoologisch-Botanische Datenbank/Zoological-Botanical Database

Digitale Literatur/Digital Literature

Zeitschrift/Journal: [Mammalian Biology \(früher Zeitschrift für Säugetierkunde\)](#)

Jahr/Year: 1973

Band/Volume: [39](#)

Autor(en)/Author(s): Park A. Wallace, Benstead Mary, Nowosielsky-Slepowron B. J. A.

Artikel/Article: [Biology of the rice rat \(\*Oryzomys palustris natator\*\) in a laboratory environment 103-109](#)