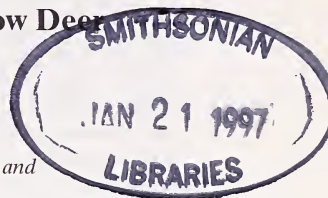




Functional morphology of metatarsal glands in Fallow Deer (*Cervus dama*)

By M. APOLLONIO and G. VAILATI

Animal Behaviour and Anthropology Department, University of Pisa and
Biology Department, University of Milan, Italy



Receipt of Ms. 10. 11. 1995
Acceptance of Ms. 30. 07 1996

Abstract

Samples of metatarsal glands were studied from fallow deer (*Cervus dama*), of different age and sex classes collected in September, October, November, and March. The amount of sebaceous and sudoriferous gland layers, the diameter of the apocrine tubuli, and their relative number were measured. In each sex and age class two different developmental situations were found, the sudoriferous component being mainly responsible for both. Such differences corresponded to a more or less pronounced glandular activity, evidenced by the thickness of the sudoriferous glandular dermal zone (sud-GDZ) and the density of the apocrine tubuli. Well-developed glands were significantly more prevalent in adults than in subadults and fawns. No seasonal variation was found in the rut and the post-rut period for adult females, while it was evident in adult males. In the latter, glands are underdeveloped during the rut, suggesting no relationship with the sexual hormone cycle, but become well-developed in spring, i.e. when males regroup after the rut. The obtained results suggest that the metatarsal gland in fallow deer could play a similar functional role as in black-tailed deer (i.e. to discharge alarm pheromons, being more developed in the sex and age classes involved in social groups with a leadership role).

Introduction

The metatarsal gland is one of the specialized dermal glands involved in chemical communication, and consists of enlarged holocrine and apocrine secretory units. Seasonal or sex and age variations in such structures seem to be related with behavioural changes and could provide information concerning their function; all these data are thus of interest from an ethological point of view. In cervids they are present both in Cervinae and Odocoileinae (GOSLING 1985) and have been especially well studied in the latter (HERSHKOVITZ 1958; QUAY 1959; QUAY and MÜLLER-SCHWARZE 1970; MÜLLER-SCHWARZE 1971). In black-tailed deer (*Odocoileus hemionus columbianus*), MÜLLER-SCHWARZE 1971 demonstrated their function in releasing scent in “fear-inducing” situations. For fallow deer POCK (1910) and ALVAREZ et al. (1975), gave only an external description, while the histology of this gland in *Cervus dama* was described by ZIETZSCHMANN (1903), BRINKERMANN (1912) and SCHAFFER (1940) although no functional explanation was given.

Here we describe the histology of the metatarsal gland in fallow deer and we attempt to use histological data concerning different sex and age classes and different periods in order to assess:

- i) any differences in sex and age classes possibly linked with a functional explanation
- ii) any seasonal fluctuations of metatarsal gland activity likely to be dependent on sexual hormone cycle.

Materials and methods

Metatarsal glands were collected from 198 fallow deer culled from September to December during the years 1985, 1986, 1987, and 1992 in the San Rossore Preserve near Pisa, Italy. Samples were fixed in Bouin's fluid. Skin samples were dissected into easy to handle pieces by removing a strip from the center of the metatarsal gland. Sections 10 μm in thickness were stained with Mayer's acid alum hematoxylin and eosin. The thickness of the glandular dermal zone (GDZ, subdivided into sebaceous glandular dermal zone, seb-GDZ, and sudoriferous glandular dermal zone, sud-GDZ), the outer diameter of the apocrine tubuli and their density were measured with the aid of an ocular micrometer. The thickness of GDZ refers to the dermal portion actually occupied by glandular layers, discounting strips showing only connective tissue. It was measured where glandular tissue was most developed. The density of sudoriferous tubuli was determined referring to a reticulum of 1.562 square millimeter placed at the middle of the measurement Y axis. Their mean outer diameter was obtained from the values of 10 tubuli randomly chosen inside the reticulum (cf. MOSSING and KÄLLQUIST 1981). Variations in the amount of secretory tissue have been used to indicate the extent of secretory activity; therefore, we distinguished between developed and non-developed glands considering both sudoriferous and sebaceous components and we tested the measurements described above for all sex and age differences. The age classes, determined by dentition and antlers dimensions and shape, were as follows: male and female fawns between 4 and 10 months old; male and female yearlings between 15 and 21 months; adult males and females older than 27 months. Statistical analyses included Kruskal-Wallis Anova, Mann-Whitney U-test, χ^2 and Fisher exact test.

Results and discussion

The metatarsal gland in fallow deer shows two glandular components: one displaying superficial aciniform sebaceous secretory units and a second with deep tubular sudoriferous bodies (Fig. 1). The overlying skin is intensely pigmented and a circumglandular hair

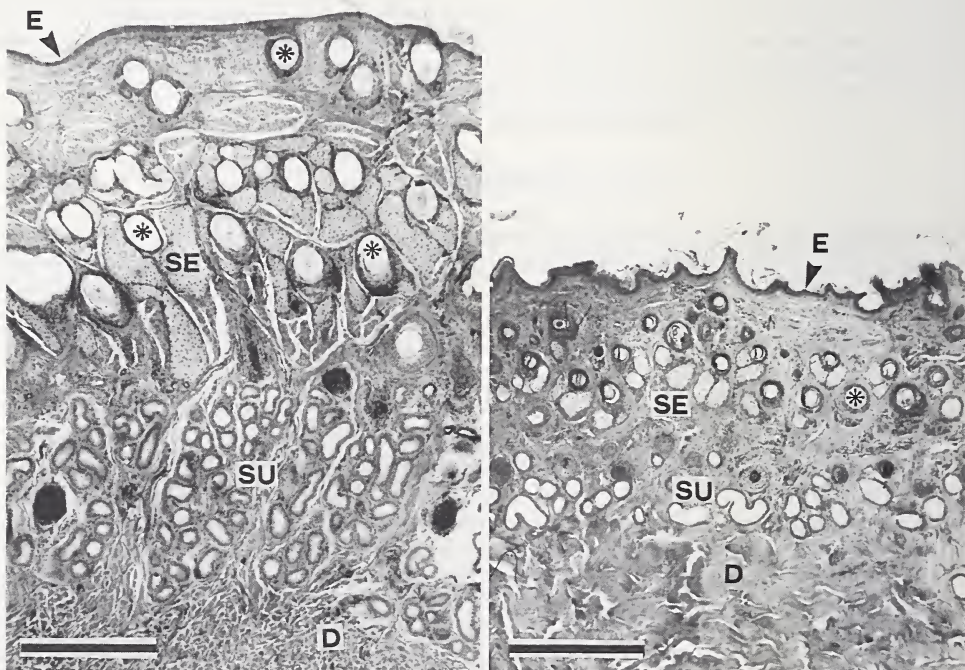


Fig. 1. Developed (left) and non-developed (right) metatarsal glands of adult fallow deer females. Scale bar is 0.5 mm, * = hair follicle, D = dermis, E = epidermis, SE = sebaceous glands, SU = sudoriferous glands.

tuft is present. In the centre of this area the keratinized ridge present in *Odocoileus* (QUAY 1959; QUAY and MÜLLER-SCHWARZE 1970) is absent. Overall thickness is 3–4 mm, depending on the development of glandular components. The epidermis covering the glandular area is about 50 µm thick and consists of a pluristratified keratinized epithelium with 4–6 cellular rims and a thin stratum corneum. The underlying corium is about 0.5 mm thin. The sebaceous component consists of irregularly shaped bulbs about 200 µm wide, usually connected with smooth musculature (erector pili) of about 150 µm. The excretory duct of these bulbs opens into the higher tract of the pilosebaceous follicle near the open surface. The sudoriferous component shows many glomerular apocrine glands whose tubuli have an outer diameter of 70–100 µm and are surrounded by a monostratified cubic epithelium of 7–15 µm. Their excretory ducts are very thin and open inside a piliferous follicle above the level at which the sebaceous glands open. Unlike in *Odocoileus* (QUAY 1959; QUAY and MÜLLER-SCHWARZE 1970), sudoriferous units do not form a compact glandular layer, but are separated by slender connective tissue. Close to the sudoriferous tubuli myoepithelial cells are numerous and observable. Differences in metatarsal gland development concern sebaceous and sudoriferous components; higher values for thickness being 1.3 mm in sebaceous glands and 1.25 in sudoriferous glands, and the lower values about 185–187 µm in both of them. Age and sex classes showed differences in the thickness of the sudoriferous component ($p < 0.00001$, K-W Anova) but not in the thickness of the sebaceous component.

Histological description of this gland is comparable to the findings of ZIETZSCHMANN (1903) and SCHAFER (1940). However, we observed developmental differences in age and sex classes in the sudoriferous but not in the sebaceous component; this does not correlate with the results of SCHAFER (1940). Analysing seven individuals only, this author found such differences in the sebaceous but not in the sudoriferous component. The sudoriferous component showed remarkable differences in age and sex classes in spite to what was observed by QUAY and MÜLLER-SCHWARZE (1970) in black-tailed deer. It should be taken into account that these authors considered six males and one female only.

To look for differences among age and sex classes in the proportion of developed and non-developed glands, we qualitatively discriminated the two categories of development in relation to the thickness of seb-GDZ and sud-GDZ. This evaluation was tested with Mann-Whitney U-test for each sex and age class for the sudoriferous component by the use of the sud-GDZ thickness, tubuli density (TD) and tubuli diameter (TDI) in a sample of ten (or fewer when not available) developed and non-developed glands. Sud-GDZ and TD proved to fit well with the evaluation, as significant differences were observed between developed and non-developed glands in all cases but one (subadult females, sud-GDZ, $P = 0.07$). Some comparisons were then performed with χ^2 test. Differences were found between age classes, both with cumulated and segregated sex classes, but not be-

Table 1. Mean thickness value \pm SE expressed in µm of sudoriferous and sebaceous glandular dermal zones (sud-GDZ and seb-GDZ) of metatarsal glands in different age and sex classes in fallow deer.

Sex and age class	No. of samples	Mean thickness of sudoriferous glandular dermal zone	Mean thickness of sebaceous glandular dermal zone
Female fawns	35	412 \pm 145	807 \pm 215
Yearling females	21	496 \pm 145	826 \pm 263
Adult females	42	660 \pm 245	874 \pm 244
Male fawns	23	431 \pm 110	766 \pm 230
Yearling males	51	584 \pm 209	763 \pm 216
Adult males	26	756 \pm 263	814 \pm 185

Table 2. Comparisons made with χ^2 of proportion of developed and non-developed metatarsal glands with respect to the sudoriferous component in different age and sex classes. From above a) comparison between age classes, b) comparison between age classes in males and c) females, d) comparison between sexes within the same age class.

All			
	Adults	Yearlings	Fawns
Adults	—	$\chi^2 = 13.29$ $p < 0.001$	$\chi^2 = 21.93$ $p < 0.001$
Yearlings		—	$\chi^2 = 4.25$ $p < 0.05$
Fawns			—

Males			
	Adults	Yearlings	Fawns
Adults	—	$\chi^2 = 0.26$ $p > 0.5$ N.s.	$\chi^2 = 4.42$ $p < 0.05$
Yearlings		—	$\chi^2 = 2.63$ $p > 0.10$ N.S.
Fawns			—

Females			
	Adults	Yearlings	Fawns
Adults	—	$\chi^2 = 9.13$ $p < 0.005$	$\chi^2 = 16.62$ $p < 0.001$
Yearlings		—	$\chi^2 = 0.078$ $p > 0.75$ N.S.
Fawns			—

	Adult females	Yearling females	Female fawns
Adult males	$\chi^2 = 0.47$ $p > 0.25$ N.S.		
Yearling males		$\chi^2 = 1.54$ $p > 0.1$ N.S.	
Male fawns			$\chi^2 = 0.0008$ $p > 0.975$ N.S.

tween sex classes of the same age (Tab. 2). Differences between developed and non-developed glands within each category for the sebaceous component was based only on the thickness of the seb-GDZ. This evaluation was tested as described above with a comparison of ten developed and non-developed glands for each sex and age class, and proved to fit well in all cases. However, no differences were found in the proportion of developed and non-developed glands with respect to the sebaceous component in the various age or sex classes.

An interpretation of the functional role of metatarsal glands lies in the different development of the sudoriferous and the sebaceous components. Only the former showed developmental differences between age classes and this component in some cervids could develop volatile pheromones, favouring rapid olfactory communication. The metatarsal gland of black-tailed deer, for example, produces a scent that acts as an alarm pheromone. This scent is attributable to the sudoriferous secretion, and has a low concentration and is highly volatile (MÜLLER-SCHWARZE 1971). Considering the close relationship of the two species, it would not be surprising if metatarsal glands in fallow deer serve a similar function. The higher developmental level reached by the sudoriferous component in adult fallow deer could depend on the higher social responsibility of this age class: adult females, particularly, maintain a permanent link with their fawns (BRAZA 1975; SCHAAL 1982) and often play a leader role in herds (HEIDEMANN 1973; BRAZA 1975). A further element to be considered is the higher vigilance activity of adult females in comparison to other age and sex classes reported by SCHAAL and ROPPARTZ (1985).

Seasonal changes between rut and post-rut periods were documented by statistical analysis within the various age and sex classes only for adult males (Fisher exact test $p = 0.013$) who showed higher proportions of developed metatarsal glands in the post-rut period. This result suggests a possible connection with the dissolution of male herds during the breeding season due to the arousal of interindividual aggression. Since, at this time, males do not maintain other social relationships than intense competition for females, the scent alarm communication would be quite useless. In our opinion this seasonal variation therefore should not be interpreted as depending on sexual hormones as in the cases of preputial glands of adult fallow deer males (KENNAUGH et al. 1977) or suborbital glands in reindeer (MOSSING and KÄLLQUIST 1981). Metatarsal gland activity in adult fallow deer males seems in fact to be depressed by breeding activities and the consequent increase of testosterone.

Acknowledgements

We are most grateful to the staff of the San Rossore Presidential Estate for their help in collecting samples. We gratefully acknowledge the help of ROBERTO COLOMBO who greatly improved this manuscript both in concepts and style.

Zusammenfassung

Funktionsmorphologie der Metatarsaldrüsen beim Damhirsch (Cervus dama)

Es wurden Metatarsaldrüsen von Damhirschen (*Cervus dama*) unterschiedlichen Alters und Geschlechtes untersucht. Die erforderlichen Proben wurden in den Monaten September, Oktober, November und März gesammelt. Die Ausbildung des sebazeischen und sudoriferen Stratum sowie der Durchmesser und die relative Anzahl der apokrinen Tubuli wurden gemessen. In jeder Alters- und Geschlechtsklasse wurden zwei unterschiedliche Entwicklungszustände gefunden. Die Unterschiede entsprachen einer mehr oder weniger ausgeprägten Drüsenaktivität, wie sie durch die Dicke des sudoriferen Stratum und die Dichte der apokrinen Tubuli nachgewiesen wurde. Gut entwickelte Drüsen traten signifikant häufiger bei Adulten als bei Subadulten und Kälbern auf. Bei den weiblichen Tieren zeigten sich zwischen der Brunftperiode und der Zeit danach keine Unterschiede in der Drüsenreife. Bei den Hirschen waren die Drüsen während der Brunft unterentwickelt, was auf einen fehlenden Zusammenhang mit dem Zyklus der Geschlechtshormone hindeutet. Beim Wiedereintreten der Hirsche in Männchengruppen nach der Brunft waren die Drüsen jedoch gut entwickelt. Nach diesen Ergebnissen scheinen die Metatarsaldrüsen beim Damhirsch dieselbe Funktion zu haben wie beim Schwarzwedelhirsch, nämlich die Abgabe von Warnpheromonen. Diese Funktion ist in jenen Alters- und Geschlechtsklassen stärker ausgeprägt, in denen soziale Gruppen und die Führerrolle von Einzeltieren von Bedeutung sind.

References

- ALVAREZ, F.; BRAZA, F.; NORZAGARAY, A. (1975): Estructura social del gamo (*Dama dama*, Mammalia, Cervidae) en Donana. Ardeola **21** (Especial), 1129–1142.
- BRAZA, F. (1975): Censo de gamo (*Dama dama*) en Donana. Naturalia Hispanica, **3** ICONA, 1–27.
- BRINKERMANN, A. (1912): Die Hautdrüsen der Säugetiere (Bau und Sekretionsverhältnisse). Erg. Anat. Entw. **20**, 1173–1231.
- GOSLING, L. M. (1985): The even toed ungulates: order Artiodactyla. Sources, behavioural context, and function of chemical signals. In: Social odours in mammals, Ed. by R. E. BROWN and D. W. MACDONALD. Oxford: University Press. Pp. 550–618.
- HEIDEMANN, G. (1973): Zur Biologie des Damwildes (*Cervus dama* L., 1758). Hamburg, Berlin: Verlag Paul Parey.
- HERSHKOVITZ, P. (1958): The metatarsal glands in white-tailed deer and related forms of the Neotropical Region. Mammalia **22**, 537–546.
- KENNAUGH, J. H.; CHAPMAN, D. I.; CHAPMAN, N. G. (1977): Seasonal changes in the prepuce of adult fallow deer (*Dama dama*) and its probable function as a scent organ. J. Zool. (London) **183**, 301–310.
- MOSSING, T.; KÄLLQUIST, L. (1981): Variations in cutaneous glandular structures in reindeer (*Rangifer tarandus*). J. Mammalogy **62**, 606–612.
- MÜLLER-SCHWARZE, D. (1971): Pheromones in black-tailed deer (*Odocoileus hemionus columbianus*). Anim. Behav. **19**, 141–152.
- POCOCK, R. I. (1910): On the specialized cutaneous glands of ruminants. Proc. Zool. Soc. London. Pp. 840–986.
- QUAY, W. B. (1959): Microscopic structure and variation in the cutaneous glands of the deer, *Odocoileus virginianus*. J. Mammalogy **40**, 114–128.
- QUAY, W. B.; MÜLLER-SCHWARZE, D. (1970): Functional histology of integumentary glandular regions in black-tailed deer (*Odocoileus emionus columbianus*). J. Mammalogy **51**, 675–694.
- SCHAAL, A. (1982): Influence de l'environnement sur le composantes du groupe social chez le daim cervus (*Dama dama* L.) Rev. Ecol. Terre Vie **36**, 161–174.
- SCHAAL, A.; ROPPARTZ, P. (1985): Le comportement de surveillance chez le Daim (*Dama dama*): effet de variables liées a l'individu, au groupe social et a l'habitat. C.R. Acad. Sc. Paris, t. 301, Serie III, **16**, 731–736.
- SCHAFER, J. (1940): Die Hautdrüsenorgane der Säugetiere mit besonderer Berücksichtigung ihres histologischen Aufbaues und Bemerkungen über die Proktodäaldrüsen. Berlin, Wien: Urban und Schwarzenberg.
- ZIETZSCHMANN, E. H. (1903): Beiträge zur Morphologie und Histologie einiger Hautorgane der Cerviden. Z. wiss. Zool. **74**, 1–63.

Authors' addresses: MARCO APOLLONIO, Dipartimento di Scienze del Comportamento Animale e dell' Uomo, Università di Pisa, Via Volta 6, I-56126 Pisa and GIANNI VAILATI, Dipartimento di Biologia, Università di Milano, Via Celoria 26, I-20133 Milano, Italy.

ZOBODAT - www.zobodat.at

Zoologisch-Botanische Datenbank/Zoological-Botanical Database

Digitale Literatur/Digital Literature

Zeitschrift/Journal: [Mammalian Biology \(früher Zeitschrift für Säugetierkunde\)](#)

Jahr/Year: 1996

Band/Volume: [61](#)

Autor(en)/Author(s): Apollonio Marco, Vailati Ginni

Artikel/Article: [Functional morphology of metatarsal glands in Fallow deer \(*Cervus dama*\) 321-326](#)