



Substitution of the deciduous premolar in *Chaetomys subspinosus* (Olfers, 1818) (Hystricognathi, Rodentia) and its taxonomic implications

By G. CARVALHO

Lab. Sist. & Evo. de Mamíferos (Mastozoologia), Departamento de Vertebrados, Museu Nacional, Universidade Federal do Rio de Janeiro, Rio de Janeiro, Brazil

Receipt of Ms. 31. 05. 1999

Acceptance of Ms. 27. 12. 1999

Key words: *Chaetomys subspinosus*, Hystricognathi, deciduous forest, premolars, taxonomy

The bristle-spined porcupine, *Chaetomys subspinosus* (Olfers, 1818), is a New World hystricognath rodent endemic to the Brazilian Atlantic rainforest, whose geographical distribution ranges from northern Rio de Janeiro State up to Sergipe State (SANTOS, et al. 1987). The taxonomic position of the monotypical genus *Chaetomys* has been very controversial, having been considered either as a member of the Erethizontidae (e.g.: THOMAS 1897; ELLERMAN 1940; LANDRY 1957) or of the Echimyidae (e.g.: MILLER and GIDLEY 1918; PATTERSON and WOOD 1982).

In his general work with the taxonomy of hystricognath rodents, WOODS (1993) lists *Chaetomys* in the family Echimyidae, as suggested by PATTERSON and WOOD (1982) due to the supposed retention of the deciduous premolars (dP4), an echimid-derived character. This placement of *Chaetomys* within the Echimyidae was strongly contested by MARTIN (1994), who pointed out that *C. subspinosus* lacks the rectangular plate-like interprismatic matrix in the portio interna of the incisor Schmelzmuster (multiserial-right angular incisor enamel microstructure). This character has been considered a key synapomorphy of Octodontoidea, the superfamily, which includes the family Echimyidae. Furthermore, MARTIN (1994) stated, in contrast to PATTERSON and WOOD (1982), that the posterior carotid foramen is in fact present in *Chaetomys*, a condition shared with the erethizontids but not with the echimyids. MARTIN (1994) could not however, find any evidence against the retention of the deciduous premolar in *Chaetomys*.

While examining a sample of 12 specimens of *C. subspinosus* housed at the Museu Nacional, Rio de Janeiro, Brazil, the present author found one specimen (MN 11464) whose successional premolars (P4) could be seen erupting when the deciduous premolars (dP4) were removed (Fig. 1). This condition was found in both the lower and the upper molar series. The dP4 were only slightly more worn than the first molars and were similar in size and crown morphology to the P4. Almost all cranial sutures in this specimen were obliterated and all molar teeth already worn, which indicate the maturity of the specimen (Voss and ANGERMANN 1997).

None of the other available specimens were found to be in a similar state of tooth replacement (however, in two of these, MN 11202 and MN 11461, it was not possible to remove any of the premolars for observation). Likewise, a premolar clearly less worn than the first molar in a complete molar series, which also would be evidence for premolar substitution, was not present in any of the specimens. This raises the question whether the observed substitution of the dP4 commonly takes place in *Chaetomys*, or whether the observed erupting premolar is an anomalous individual condition.

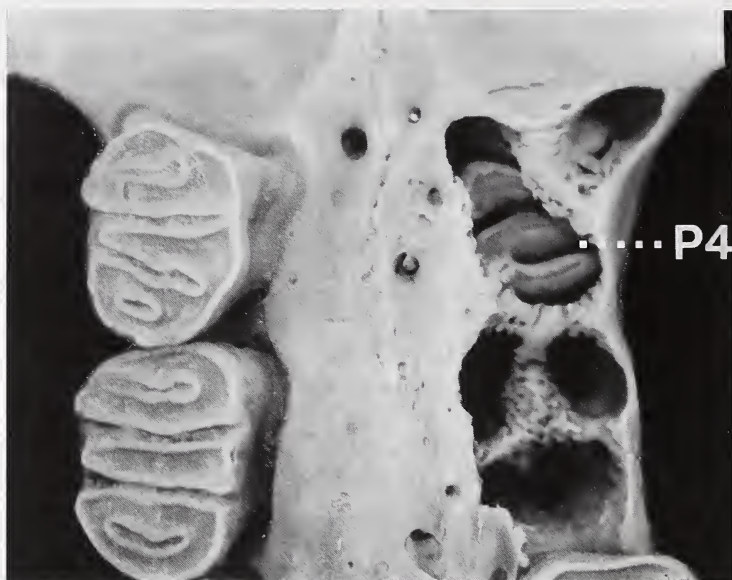

Fig. 1. Anterior portion of upper molar series of the specimen MN 11464 showing the left successional premolar (P4) after the removal of the deciduous tooth.

In order to investigate this question, the sample was divided into two separate groups, depending on whether the specimens seemed to be younger or older than the specimen displaying the erupting P4 (MN 11464). The features used for this relative age characterization were the wear of the molar teeth and the closure of cranial sutures (VOSS and ANGERMANN 1997). It could be assumed that all premolars in the group of younger specimens would be a dP4, while those in the group of older specimens would be a P4. Thus, any character that could be used to distinguish between a dP4 and a P4 should be consistently different in these two groups.

Eight specimens (MN 9680, MN 11202, MN 11459, MN 11460, MN 11461, MN 11462, MN 50682, and MN 50683) were considered to be younger than the specimen with erupting P4 (MN 11464). Only three specimens (MN 11465, MN 34503, MN 46250) were considered to be older. The morphology of the anterior roots of the upper premolar was consistently different in the specimens of the two groups. The specimens of the younger group presented the two anterior roots of the upper premolars to be divergent and well separated, similar to the anterior roots of the upper dP4 of MN 11464 (Fig. 2a). In contrast, in all specimens of the older group, the two anterior roots were nearly parallel and fused proximally (Fig. 2b). Following these results it can be concluded that this character can be used to distinguish the dP4 from the P4, a finding that supports the supposition, that the substitution of dP4 generally occurs in *Chaetomys*. The substitution of the dP4 in *Chaetomys* corroborates the exclusion of the genus from the family Echimyidae as proposed by MARTIN (1994). This, however, does not add information about its taxonomic affinities, since the substitution of dP4 is considered a plesiomorphic feature for the Hystricognathi.

MARTIN (1994) has also pointed out that the presence of a posterior carotid foramen and the small enamel thickness of the incisor, with its primitive Schmelzmuster, should be regarded as primitive traits for the Hystricognathi, and hence should not be used as an indication to place *Chaetomys* in the family Erethizontidae. However, in a more recent publication, BRYANT and MCKENNA (1995) suggested that the presence of an internal car-

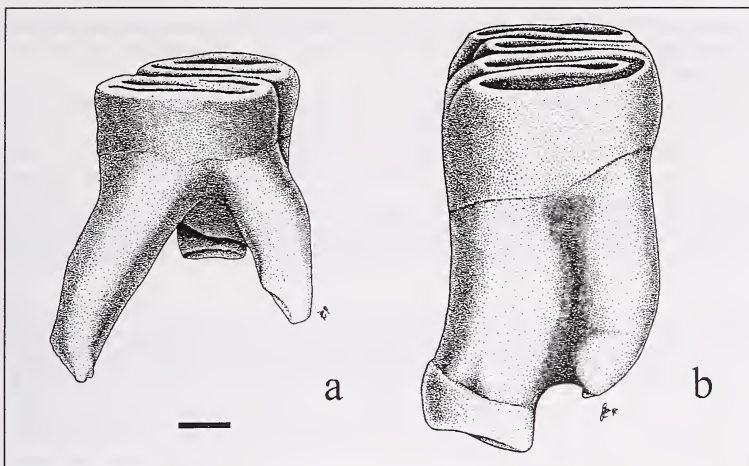


Fig. 2. Anterior roots of the upper premolars of *Chaetomys subspinosus*. a) divergent and well-separated anterior roots of a left upper deciduous premolar (MN 11464); b) proximally fused parallel anterior roots of a left upper premolar of an older adult (MN 34503), supposedly a successional premolar. Scale bar = 1 mm

otid artery, although a primitive condition for rodents, emerges as a synapomorphy of the Erethizontidae within the Hystricognathi, for which the absence of an internal carotid artery is the primitive condition. Hence, the presence of the posterior carotid foramen in *Chaetomys* should actually be reinterpreted as evidence for its association with the Erethizontidae.

Acknowledgements

I would like to thank JAIR DA SILVA for drawing the illustrations and LEANDRO SALLES for taking the photographs. JULIE BRODEUR kindly revised the English text. I am also indebted to ARIANNA CAMARDELLA, CLAUDIA RUSSO, JOÃO A. OLIVEIRA, and LEANDRO SALLES, who provided valuable comments on previous versions of this manuscript. This research was supported by a graduate fellowship from CAPES (Ministry of Education, Brazil).

References

- BRYANT, J. D.; MCKENNA, M. C. (1995): Cranial anatomy and phylogenetic position of *Tsaganomys altaicus* (Mammalia: Rodentia) from the Hsanda Gol Formation (Oligocene), Mongolia. *Am. Mus. Nov.* **3556**, 1–42.
- ELLERMAN, J. R. (1940): *The Families and Genera of Living Rodents*. Vol. 1. London: Trustees of the British Museum (Natural History).
- LANDRY, S. O. (1957): The interrelationships of the New and Old World hystricomorph rodents. *Univ. Calif. Publ. Zool.* **56**, 1–118.
- MILLER, G. S. JR.; GIDLEY, J. W. (1918): Synopsis of the supergeneric groups of rodents. *J. Wash. Acad. Sci.* **8**, 431–448.
- MARTIN, T. (1994): On the systematic position of *Chaetomys subspinosus* (Rodentia: Caviomorpha) based on evidence from the incisor enamel microstructure. *J. Mamm. Evol.* **2**, 117–131.
- PATTERSON, B.; WOOD, A. E. (1982): Rodents from the Desadean Oligocene of Bolivia and the relationships of the Caviomorpha. *Bull. Mus. Comp. Zool.* **149**, 371–573.

- SANTOS, I. B.; OLIVER, W. L. R.; RYLANDS, A. B. (1987): Distribution and status of two species of tree porcupines, *Chaetomys subspinosus* and *Sphiggurus insidiosus*, in south-east Brazil. Dodo, J. Jersey Wildlife Preserv. Trust **24**, 43–60.
- THOMAS, O. (1897): On the genera of the rodents: an attempt to bring up to date the current arrangement of the order. Proc. Zool. Soc. Lond. **1896**, 1012–1028.
- VOSS, R. S.; ANGERMANN, R. (1997): Revisionary notes on Neotropical porcupines (Rodentia: Erethizontidae). 1. Type material described by Olfers (1818) and Kuhl (1820) in the Berlin Zoological Museum. Am. Mus. Nov. **3214**, 1–44.
- WOODS, C. A. (1993): Suborder Hystricognathi. In: Mammal Species of the World. Ed. by D. E. WILSON and D. A. M. REEDER. Sec. ed. Washington, London: Smithsonian Inst. Press. Pp. 789 ff.

Author's address: GUILHERME AUGUSTO DOS SANTOS CARVALHO, Lab. Sist. & Evo. de Mamíferos (Mastozoologia), Departamento de Vertebrados, Museu Nacional, Quinta da Boa Vista s/n° Rio de Janeiro, Brasil. CEP: 20940-040. e-mail: winther@unisys.com.br

ZOBODAT - www.zobodat.at

Zoologisch-Botanische Datenbank/Zoological-Botanical Database

Digitale Literatur/Digital Literature

Zeitschrift/Journal: [Mammalian Biology \(früher Zeitschrift für Säugetierkunde\)](#)

Jahr/Year: 2000

Band/Volume: [65](#)

Autor(en)/Author(s): Carvalho Guilherme Augusti dos Santos

Artikel/Article: [Substitution of the deciduous premolar in *Chaetomys subspinosus* \(Olfers, 1818\) \(Hystricognathi, Rodentia\) and its taxonomic implications 187-190](#)