



Original investigation

The vomeronasal complex in strepsirhine primates and *Tarsius*

By ANGELA WÖHRMANN-REPENNING and M. BERGMANN

Zoologie und Vergleichende Anatomie, Universität Kassel, Kassel

Receipt of Ms. 11. 09. 2000

Acceptance of Ms. 05. 03. 2001

Abstract

The vomeronasal complex (VNC) of several different strepsirhine primates and two *Tarsius* species was studied with respect to comparative anatomy. All investigated species possess a well developed vomeronasal organ (VNO) in the center of this complex. As *Tarsius* possesses an extremely small nose, a correspondingly small VNO is present. Its organ is – different to the Strepsirhini and most other mammals – almost completely outlined by an olfactory epithelium. With regard to its histological appearance, however, the VNO should play an important role in all investigated primates concerning sensory ability. It is evident that the VNC in primates follows the progressive developmental line of placental mammals. In this connection the rostral part of the paraseptal cartilage is an intricate structure and normally forks into a dorsal and a ventral branch, where the latter usually fuses with the cartilage of the nasopalatine duct. While several Strepsirhini fit into this pattern, some other tend to differ from this scheme, mainly caused by nasal metamorphosis connected with facial reorganisations. All Strepsirhini possess a naked rhinarium split ventrally by a median philtrum, which communicates with the sulcus papillae palatinae. Inside this sulcus, taste buds occur quite frequently at the lateral walls of the palatine papilla. *Tarsius* a haplorhine primate differs completely by having an unsplit, freely movable, hairy upper lip.

Key words: *Tarsius*, Strepsirhini, vomeronasal organ, vomeronasal complex

Introduction

The vomeronasal organ (VNO) is a paired accessory olfactory organ present in most mammals and located at the base of the rostral nasal septum. This organ belongs to an autonomous intranasal system with a complicated morphology called the vomeronasal complex (VNC) (BROOM 1898; WÖHRMANN-REPENNING 1984 a, b). The comparative anatomy of this VNC testifies to its

functional importance (BAILEY 1978; WÖHRMANN-REPENNING 1991) and allows limited conclusions concerning phylogenetic relationships within the class of mammals (BROOM 1898; WÖHRMANN-REPENNING 1984 a, b, 1993 b). As a rule, the morphology of the VNC within a mammalian order follows the same type of construction, and usually the respective species show little in-

dividual variations. Those orders that do not fit into this scheme, like insectivores (WÖHRMANN-REPENNING 1984b) and bats (WIBLE and BHATNAGAR 1996), are of particular interest. From this point of view, the order of primates should be of special significance, since it is well known that within the ascension of this order the sense of smell has decreased from macro- to microsmaty. Involved in this process are both olfactory systems, the primary nasal, as well as the vomeronasal olfaction, which in the catarrhine radiation might even have been lost entirely (FRETS 1912; MAIER 1997).

Beyond the fact that the facial skull in primates was subject to considerable change during phylogeny (STARCK 1953; BIEGERT 1957; HOFER and SPATZ 1963) in this process the eyes oppressed the nasal cavity by moving progressively into a frontal position. In

general, the nose tended to shorten in length almost simultaneously, with the VNC involved.

Only few specific publications on the VNC of some species are available (SCHILLING 1970; JORDAN 1972; HEDEWIG 1980; STARCK 1982; MAIER 1997; BHATNAGAR and MEISAMI 1998). Reference was made to these publications, since they helped to complete the present study whose purpose is to investigate the comparative anatomical characteristics of the VNC in a greater number of mainly basale primates with regard to recorded developmental inquiries.

Material and methods

For the present study the noses of several, mainly adult primates were available as follows:

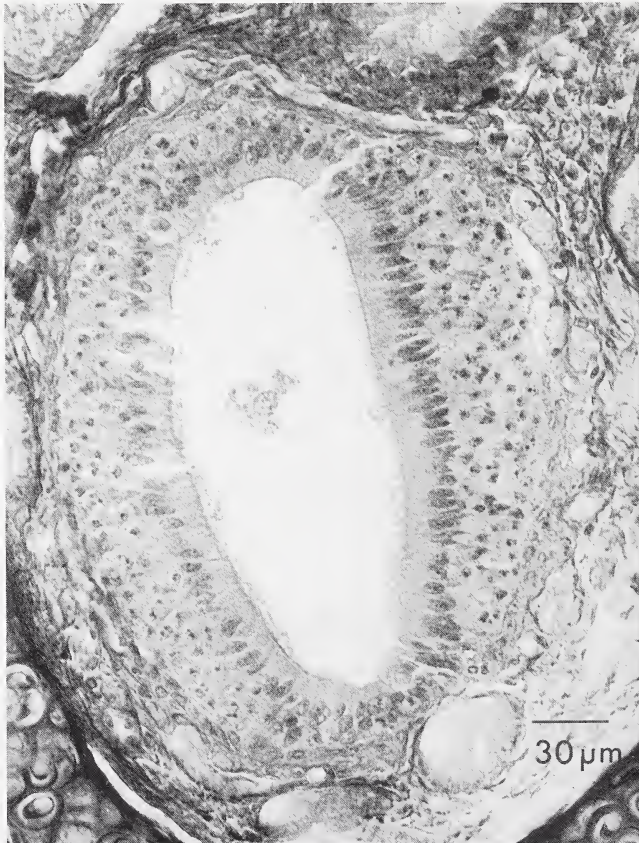


Fig. 1. Cross section of the VNO of *Tarsius bancanus borneanus*. 10 μm. Azan.

Subordo Strepsirhini: *Microcebus murinus* (Cheirogaleidae, Lemuroidea), *Lemur catta* (Lemuridae, Lemuroidea), *Arctocebus calabarensis* (Lorisidae, Lorioidea), *Nycticebus coucang* (Lorisidae, Lorioidea), *Galago crassicaudatus*, adult and fe-

tus, 43 mm total length (Galagidae, Lorioidea) *Galago senegalensis*, neonatus (Galagidae, Lorioidea).

Subordo Haplorhini: *Tarsius bancanus borneanus* (Tarsidae), *Tarsius syrichta* (Tarsidae).

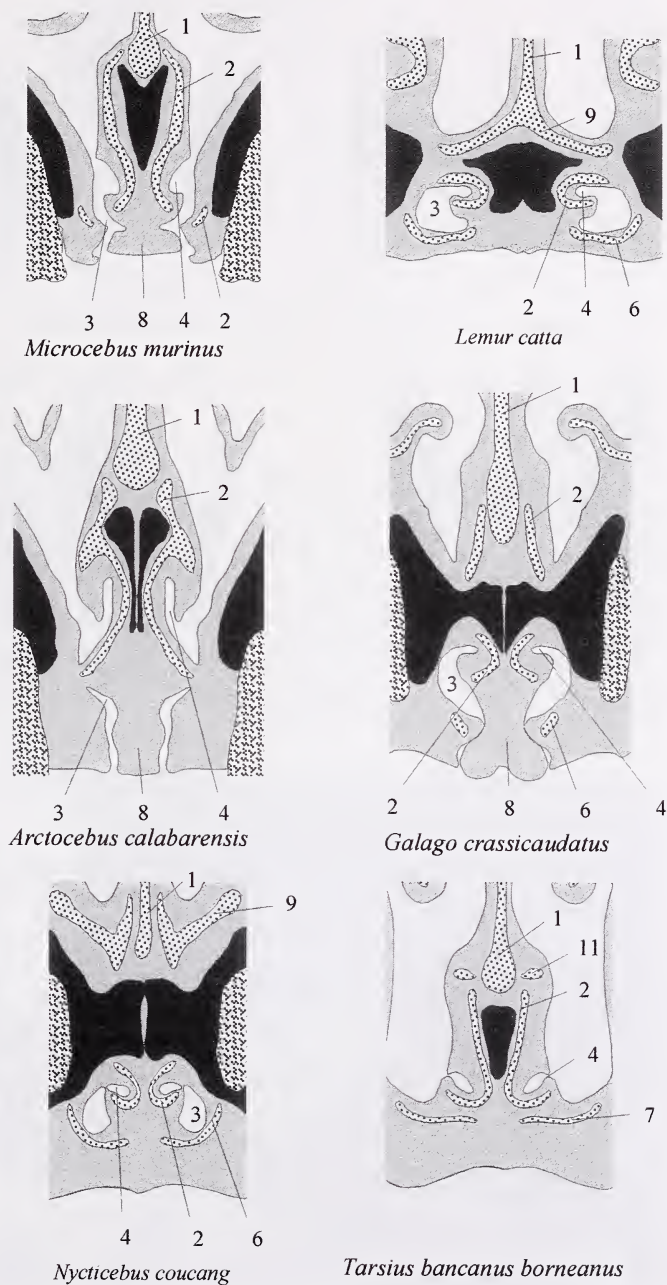
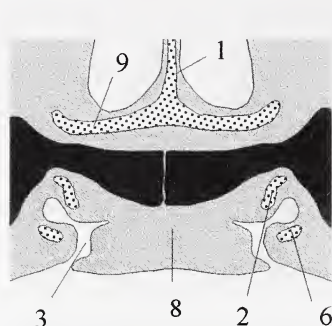


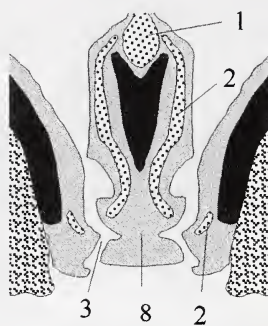
Fig. 2. Schematic and comparative representation of the merging of the VNO in the investigated species in six cross sections. Black - bone; stippled - cartilage; 1 - nasal septum; 2 - cartilago paraseptalis; 3 - ductus nasopalatinus; 4 - ductus vomeronasalis; 5 - vomeronasal organ; 6 - cartilago ductus nasopalatini; 7 - un-named cartilage; 8 - lamina transversalis anterior; 9 - outer bar; 10 - un-named cartilage; 11 - un-named cartilage.

The primate material originated to a great extent from the collection of the late Prof. Dr. H. O. HOFER. A series of differently stained cross sections

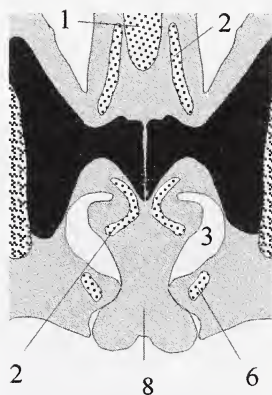
of the rostral noses were studied with the aid of a light microscope.



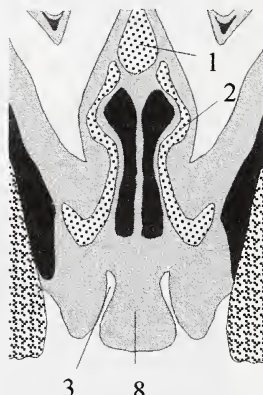
Lemur catta



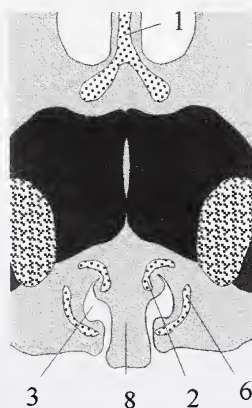
Microcebus murinus



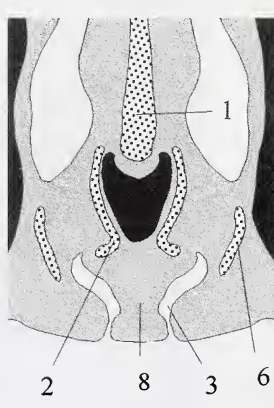
Galago crassicaudatus



Arctocebus calabarensis



Nycticebus coucang



Tarsius bancanus borneanus

Fig. 3. Schematic and comparative representation of the palatine papilla in the investigated species in six cross sections. See Fig. 2 for further explanations.

Results

Vomeronasal organ

Apparently, the VNO in all investigated primates is well developed. In Strepsirhini the sensory epithelium covers only the medial side of the organ, while the lateral part is coated by a respiratory epithelium. This coincides with the situation found in most mammals. In *Tarsius*, however, the organ is almost completely covered with olfactory epithelium, and only a few small islands of respiratory epithelium are embedded in this area (Fig. 1). This is probably a consequence of the extremely compressed snout of this species, which allows the VNO only to extend up to a length of about 3 mm. In addition, cross sections of the organ reveal it to be circularly rounded, while in most mammals the organ is somewhat laterally compressed. Rostrally, the organs of both sides merge into the paired nasopalatine ducts (Fig. 2). In *Lemur*, *Galago*, and *Nycticebus* this happens in the middle of the ducts deep inside the palate. In *Arctocebus*, as well as in *Microcebus*, the ducts penetrate the gum extremely vertically, while their VNOs merge into the ducts closely neighboured to the nasal floor. Probably therefore the orifices of the VNO are exceptionally oriented towards the oral cavity.

In *Tarsius*, cross sections show these orifices situated deep inside the nasal floor (Fig. 2). In reality, however, this region proves to be the broad funnel-shaped nasal mouth of the nasopalatine duct. In addition, the openings of the VNO are no small, short ducts like in the other species, but extended longitudinal slits.

Rostral palate and palatine papilla

All the investigated species possess a well-developed mushroom-shaped palatine papilla, which obviously has the function of a plug, as described in other mammals (WÖHRMANN-REPENNING 1991) (Fig. 3). In *Lemur*, the papilla is related to its pronounced exceptionally large snout and possesses a very broad surface. In Strepsirhini, like in all mammals with a well-developed naked rhinarium, the sulcus surrounding the lateral sides of the papil communicates directly with the philtrum, which actually is a ventral furrow splitting the rhinarium (Fig. 4). A cleft exists between their frontal incisors. In accordance their frontal incisors are separated from each other by a median cleft. *Tarsius*, however, differs from this situation (Fig. 5). As in all haplorhine primates (HOFER 1979), the tip of the nose is a rounded, hairy part connected to uniform

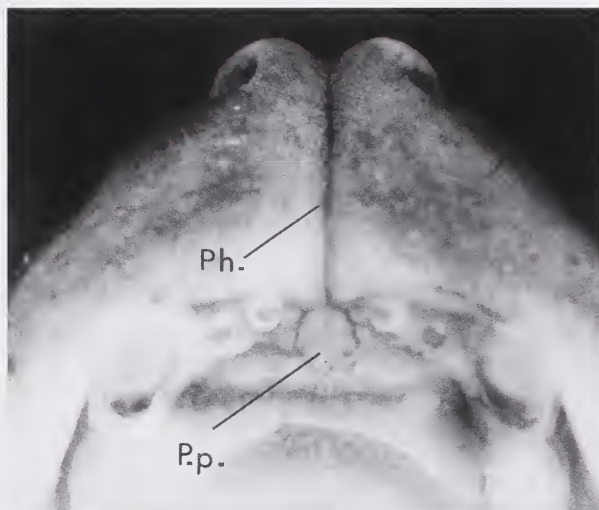


Fig. 4. Rostral view of the palate of *Galago crassicaudatus*. p.p. – palatine papilla; ph. – philtrum.

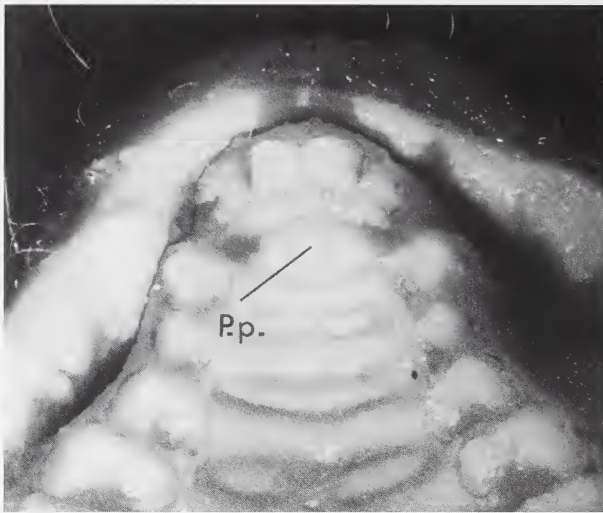


Fig. 5. Rostral view of the palate of *Tarsius bancanus borneanus*. p.p. – palatine papilla.

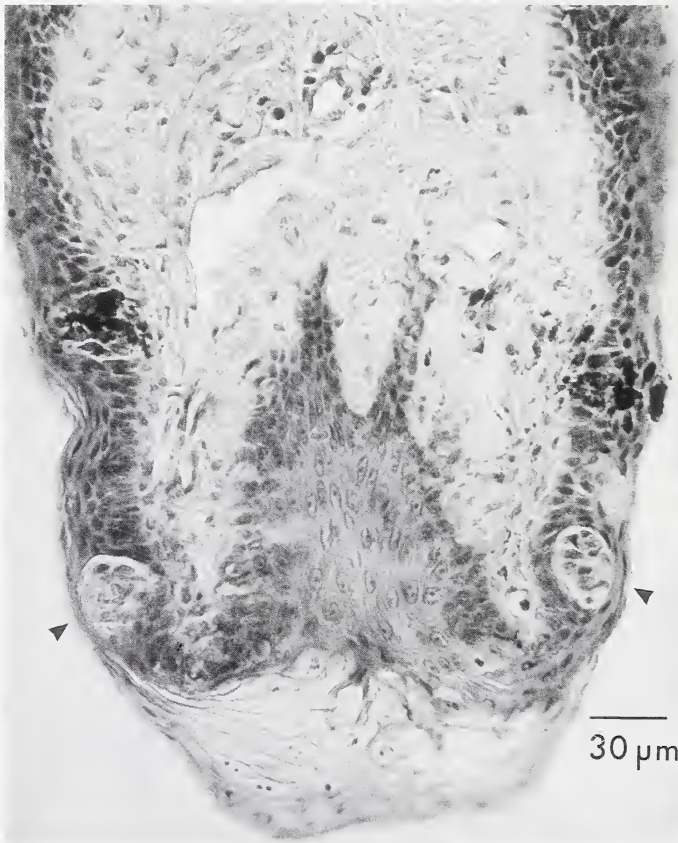


Fig. 6. Cross section of the palatine papilla of *Microcebus murinus* with taste buds (arrows). 10 µm Delafield's hematoxylin and eosin.

freely movable upper lips. No median furrow separates the incisors, instead they are situated closely together. The palatine papilla, not being very prominent, is mainly marked by two small lateral furrows, which are the actual nasal openings of the nasopalatine ducts.

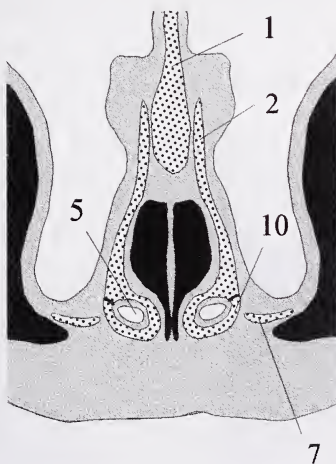
The palatine papilla is a site where taste buds quite often appear in mammals (WÖHRMANN-REPENNING 1978, 1993 a). The latter studies have shown that they do appear in several strepsirrhine primates for instance in *Galago*, *Nycticebus* and *Microcebus* (Fig. 6). HOER (1977) found taste buds in *Perodicticus potto* as well, while no taste buds occur in *Lemur*, *Arctocebus* and *Tarsius*.

Cartilages of the VNC

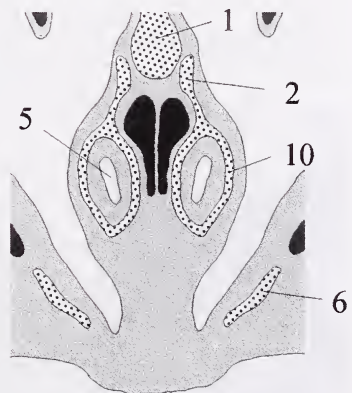
In general, the paraseptal cartilage is a central element of the VNC in mammals, since it is most closely associated to the VNO itself. It accompanies the organ along its entire length, thus forming a gutter-like support. In both Strepsirrhini and *Tarsius*, the paraseptal cartilage reveals a construction typical for most mammals. Its medial edge exceeds the lateral fold significantly in

height. An outer bar, which is a cartilaginous annular buckle often surrounding the rostral end of the VNO is not commonly distributed in the investigated primates. It is only well-developed in *Arctocebus*, where it is situated caudal to the opening of the VNO, thus forming an extended tubular structure (Fig. 7). *Nycticebus* tends to have an outer bar of varying form. One individual showed an outer bar that was developed only at its right side, while in the other animal both annular bars were developed. These bars, however, are not completely closed, with the lateral fold only showing close contact with the medial side. Here only the perichondria fuse, but not the cartilages themselves. Obviously exceptionally, there is a distinct outer bar developed in one juvenile *Galago crassicaudatus*, while this is missing in the adult specimen.

With only one exception, i.e. *Arctocebus*, the paraseptal cartilage in Strepsirrhini has a rostrally forked region. In *Microcebus*, where the organs open near the back wall of the nasopalatine ducts, this forked region occasionally is situated rostral to the opening of the organ. The dorsal branch of this fork is always continuous anterior to the lamina transversalis, while the ventral part en-



Nycticebus coucang



Arctocebus calabarensis

Fig. 7. Schematic representation of the outer bar of the paraseptal cartilage in *Nycticebus* and *Arctocebus*. See. Fig. 2 for further explanations.

circles the VNO until it opens into the nasopalatine duct. In *Tarsius*, this part is variable in its construction. Here the forked region seems to be an unstable, delicate element. While such a region was not found in the only investigated individual of *T. syrichta*, it was present in all three specimens of *T. bancanus*, but only in one case, the forked region was distinctly well developed.

In both *Nycticebus* and *Tarsius*, the ventral branch or part of the paraseptal cartilage rostrally fuses with the cartilage of the nasopalatine duct, which is common in many other mammals as well (WÖHRMANN-REPENNING 1984 a, b) From this combination a

characteristic sickle-shaped cartilage results which encircles the nasopalatine duct dorsally (Fig. 8). This seems normal for most mammals, but such a sickle is missing in individuals of *Tarsius* without a forked region. In those cases there is a solid cartilaginous nodal point instead. This sickle formed by two fused cartilages is not existent in both *Lemur* and *Galago*. A special situation is present in *Microcebus*. This species possesses a completely isolated sickle shaped cartilage. SCHILLING (1970) first described and called it "portion en faucille du cartilage paraseptal". It encircles the very rostral part of the VNO. The lateral part of this

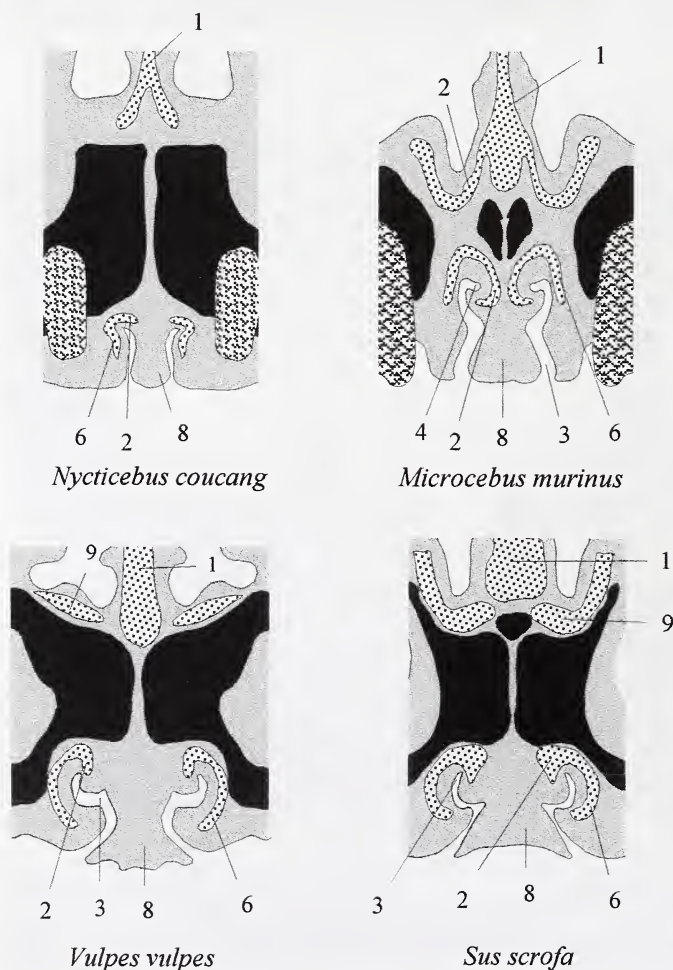


Fig. 8. A comparative representation of the sickle-shaped cartilage in two strepsirrhine primates and two non-primate mammals. See Fig. 2 for further explanations.

sickle caudally ends abruptly. This special anatomical detail will be discussed later.

All investigated species possess a palatine cartilage which serves as a horizontally orientated skeletal plug for the incisive window. Except in *Microcebus* it was found to be closely connected with the cartilage of the nasopalatine duct which supports the duct laterally.

A papillar palatine cartilage is not commonly found in the investigated primates. Moreover, this cartilage seems to occur seldomly, and irregularly. SCHILLING (1970) did not describe it in *Microcebus*, while the studied individual has a small cartilage inside the papil. Correspondingly, it is present and even well developed in only one individual of an adult *Galago crassicaudatus*.

Finally, another rather odd cartilage in *Tarsius* should be mentioned, since it tends to fuse in some cases caudally with the medial edge of the paraseptal cartilage. This element, already noted and described by STARCK (1982) supports the septal bulge situated dorsal to the VNC (Fig. 2). In *T. bancanus* it is either connected with the paraseptal cartilage or nonexistent. In *T. syrichta* it remains in certain distance to the paraseptal cartilage. This skeleton seems to be an unstable and varying element, primarily meant to stabilize a tuberosity of the nasal septum.

Discussion

From the present results it might be concluded that all strepsirhine primates and all members of the Tarsiiformes have a well developed and functionable VNO. This, however, is not surprising, since all these species possess a distinct marking behavior in which they use urine and/or special glandular secretions (EIBL-EIBESFELD 1953; SEITZ 1969; NIEMITZ 1974; EPPLE 1976) and it is suspected that especially pheromones are closely related to a functioning VNO (ESTES 1972; MEREDITH et al. 1980; SCHILLING et al. 1990; SASAKI et al. 1999). The special histological situation of the VNO in *Tarsius* might be a consequence of the narrow intranasal space in this species.

In placental mammals the VNC is either based on a primitive or a progressive type of construction. From several comparative studies it can be assumed that the origin of the division into two different lines took place during the early development of the Placentalia. Thus, we find the primitive type in Scandentia, Macroscelidea, Solenodontidae as well as in a modified form in Rodentia and Lagomorpha (BROOM 1898; WÖHRMANN-REPENNING 1980, 1981, 1982, 1984 a, b, 1987). In contrast to this, the majority of placental mammals – also including the majority of insectivores – exhibits a progressively developed VNC. In this case the rostral part of the VNO tends to subside orally, deep into the palate, where it merges directly into the nasopalatine duct, often traversing the palate in an extremely oblique manner. Due to this situation the arrangement of the cartilaginous elements is rather complicated.

There is no doubt that primates – in case they have a VNC – with regard to their construction, follow the progressively developed line. Here in this investigation we found that Strepsirhini often demonstrate a pattern which might even be called exemplary. Some studied species, however, show slight modifications which can be interpreted as first reactions to the tendency in primates to change and alter the facial skull. This, for instance, leads to some special features in *Microcebus murinus*, a species with a very short nose. The compression of its snout has obviously shifted the VNC. By this means the merging of the VNO is moved to the backside of the nasopalatine duct, and the forked region of the paraseptal cartilage is occasionally situated rostral to this site. From this aspect the isolated “sickle-shaped” cartilage (SCHILLING 1970) should be the common combination of the paraseptal cartilage and the cartilage of the nasopalatine duct, since this feature is too similar to the situation found in other mammals. Accordingly, the caudal cartilage supporting the lateral wall of the nasopalatine duct in *Microcebus* is – taking the shifted VNC into account – the rostral part of the palatine cartilage, which does not

fuse in any case with the cartilage of the nasopalatine duct. The as yet unpublished results of own investigations, show that the two cartilages develop both independently and successively to each other.

The results of the investigations conducted on *Arctocebus calabarensis* should also be discussed, since at the first sight they seem to differ greatly from the normal progressive constructional type. This impression arises from the fact that this species has no forked paraseptal cartilage and the fusion of its VNO seems to be situated rather inside the nasal cavity than in the nasopalatine duct. Cross sections, however, reveal that in this primate the VNC is orientated in an extreme vertical position. Due to this position, the VNC of *Arctocebus*, which originates without doubt from the progressive line, curiously regains features of the primitive VNC. Thus, the nasopalatine duct passes through the palate straight down to the oral cavity. Thereby the nasal floor subsides steadily into its tight crater-like opening. Thus in cross sections a misshaping impression is gained that the openings of the VNO are still situated inside the nose. Additionally, the vertical oriented VNC in *Arctocebus* renders a forked paraseptal cartilage, because the nasopalatine duct passes straight through the incisive foramen. With reference to the primitively constructed VNC, the paraseptal cartilage in *Arctocebus* has a well-developed outer bar, which, however, is rather an elongated tube than a small bar. In other strepsirhines an outer bar is more or less an exceptional structure. Finally *Tarsius* should be mentioned. It is remarkable that this species, with a nose almost completely compressed, still has a surprisingly well developed VNC (STARCK

1982). In general, it shows several conformities to those features found in strepsirhines. The forked region of the paraseptal cartilage however seems to have lost its functional importance with the very small nose. It is only well-developed in one individual. At the same time, none of the investigated species demonstrates as clearly as *Tarsius* that the VNC can be altered greatly for example, when the nasal cavity is forced to transform, and thus forced to reduce structures because of dramatic facial changes.

Regarding the external situation of the VNC in strepsirhine primates we find a situation characteristic for many mammals. These remarkable structures are closely connected to the functional mechanism of the VNO (HOFFER 1977, 1980; WÖHRMANN-REPENNING 1991). The rostral palatal features in *Tarsius* differ from this in that it belongs to the haplorhine primates. In strepsirhine primates taste buds are commonly found at the ventro-lateral sides of the papilla palatina. They are mainly situated near the entrance of the nasopalatine duct. Their role in connection with sensory abilities of the VNO in mammals was generally discussed in a previous study (WÖHRMANN-REPENNING 1993 a). The presence of taste buds indicates a dual chemosensory system combining smell and taste for functions of the VNC. In those cases, where taste buds are missing at the palatine papilla, as it can be seen in *Lemur*, *Arctocebus* and in *Tarsius*, one may assume that lingual taste buds interact with the VN-olfaction.

Acknowledgements

We would like to thank MARION KÜHN for kindly revising the English text.

Zusammenfassung

Der Vomeronasalkomplex bei strepsirhinen Primates und *Tarsius*

Der Vomeronasalkomplex (VNC) verschiedener strepsirhiner Primates und von zwei *Tarsius* Species wurde unter vergleichend anatomischen Aspekten untersucht. Alle Arten besitzen ein gut entwickeltes Vomeronasalorgan (VNO). Bei *Tarsius* ist das VNO auf Grund seiner winzigen Nasenhöhle entsprechend klein ausgebildet. Offensichtlich um dies zu kompensieren, ist das Organ – anders als bei den

Strepsirhini und den meisten anderen Mammalia – in seinem gesamten Lumen fast vollständig von olfaktorischem Epithel ausgekleidet. Das VNO aller untersuchten Primaten läßt auf Grund seiner histologischen Beschaffenheit vermuten, daß ihm eine wichtige Funktion im sensorischen Leben der Tiere zukommt. Die Befunde lassen klar erkennen, daß der VNC der Primates dem progressiv entwickelten Typus zuzuordnen ist. Charakteristisch für diese Entwicklungslinie ist ein im rostralen Abschnitt diffus gestalteteter Paraseptalknorpel, der sich zudem in diesem Bereich in der Regel in einen dorsalen und einen ventralen Ast gabelt. Beide Teile neigen zum Fusionieren mit anderen Knorpeln. Die Mehrzahl der untersuchten Primaten besitzt einen progressiv entwickelten VNC, dessen Gesamtstruktur dem anderer Mammalia bis in kleinste Details ähnelt. Bei einigen Vertretern jedoch lassen sich Besonderheiten ausmachen, die größtenteils im Zusammenhang mit der für Primates charakteristischen Umgestaltung des Fazialschädels zu sehen sind. Alle Strepsirhini besitzen ein nacktes Rhinarium, dessen Philtrum ventral mit dem Sulcus papillae palatinae kommuniziert. In diesen Sulcus aber münden die Ductus nasopalatini ein, und genau in diesem Bereich befinden sich bei einigen der untersuchten Strepsirhini Geschmacksknospen. *Tarsius* besitzt kein Rhinarium, sondern als Angehöriger der haplorhinen Primaten eine ungeteilte, behaarte, frei bewegliche Oberlippe.

References

- BAILEY, K. (1978): Flehmen in the ring-tailed lemur (*Lemur catta*). Behaviour **65**, 309–319.
- BIEGERT, J. (1957): Der Formwandel des Primatenschädels und seine Beziehungen zur ontogenetischen Entwicklung und den phylogenetischen Spezialisierungen der Kopforgane. Morph. Jb. **98**, 77–199.
- BHATNAGAR, K. P.; MEISAMI, E. (1998): Vomeronasal organ in bats and primates: Extremes of structural variability and its phylogenetic implications. Microsc. Res. Tech. **43**, 465–475.
- BROOM, R. (1996): On the comparative anatomy of the organ of Jacobson in marsupials. Proc. Linn. Soc. New South Wales **21**, 591–623.
- BROOM, R. (1998): A contribution to the comparative anatomy of the mammalian organ of Jacobson. Trans. Roy. Soc. Edinburgh **39**, 231–255.
- EPPLÉ, G. (1976): Chemical communication and reproductive processes in nonhuman primates. In: Mammalian Olfaction, Reproductive Processes, and Behavior. Ed. by R. L. DOTY. New York: Academic Press. Pp. 257–282.
- ESTES, R. D. (1972): The role of the vomeronasal organ in mammalian reproduction. Mammalia **36**, 315–341.
- FRETS, G. P. (1912): Beiträge zur vergleichenden Anatomie und Embryologie der Nase der Primaten. Morph. Jb. **44**, 409–463.
- HEDEWIG, R. (1980): Vergleichende anatomische Untersuchungen an den Jacobsonschen Organen von *Nycticebus coucang* Boddaert, 1785 (Prosimiae, Lorisidae) und *Galago crassicaudatus* E. Geoffroy, 1812 (Prosimiae, Lorisidae). Gegenbaurs morph. Jb. **126**, 543–593, 676–722.
- HOFER H. O. (1977): The anatomical relations of the ductus vomeronasalis and the occurrence of taste buds in the papilla palatina of *Nycticebus coucang* (Primates, Prosimiae) with remarks on strepsirhinism. Gegenbaurs morph. Jb. **123**, 836–856.
- HOFER, H. O. (1979): The external nose of *Tarsius bancanus borneanus* Horsfield, 1821 (Primates, Tarsiiformes). Folia primatol. **32**, 180–192.
- HOFER, H. O. (1980): The external anatomy of the oro-nasal region of primates. Z. Morph. Anthropol. **71**, 233–249.
- HOFER, H. O.; SPATZ, W. (1963): Studien zum Problem des Gestaltwandels des Schädels der Säugetiere, insbesondere der Primaten. Z. Morph. Anthropol. **53**, 29–52.
- JORDAN, J. (1972): The vomeronasal organ (of Jacobson) in Primates. Folia morphol. (Warsz.) **31**, 418–431.
- Maier, W. (1997): The nasopalatine duct and the nasal floor cartilages in catarrhine primates. Z. Morph. Anthropol. **81**, 289–300.
- MEREDITH, M.; MARQUES, D. M.; O'CONNELL, R. J.; STERN, F. L. (1980): Vomeronasal pump: Significance for male hamster sexual behavior. Science **207**, 1224–1226.
- NIEMITZ, C. (1974): A contribution to the postnatal behavioral development of *Tarsius bancanus* Horsfield, 1821, studied in two cases. Folia primatol. **21**, 250–276.
- SASAKI K.; OKAMOTO, K.; INAMURA, K.; TOKUMITSU, Y.; KASHIWAYANAGI, M. (1999): Inosi-

- tol-1,4,5-triphosphate accumulation induced by urinary pheromones in female rat vomeronasal epithelium. *Brain Res.* **823**, 161–168.
- SCHILLING, A. (1970): L'organe de Jacobson du Lémurien malgache *Microcebus murinus* (Miller 1977) Mém. Mus. Nat. Hist. Nat. Paris **61**, 203–280.
- SCHILLING, A.; SERVIERE, J.; GENDROT, G.; PERRET, M. (1990): Vomeronasal activation by urine in the primate *Microcebus murinus* a 2 DG study. *Exp. Brain Res.* **81**, 609–618.
- SEITZ, E. (1969): Die Bedeutung geruchlicher Orientierung beim Plumpflori *Nycticebus coucang* Boddaert 1785 (Prosimiae, Lorisidae) *Z. Tierpsych.* **26**, 73–103.
- STARCK, D. (1953): Morphologische Untersuchungen am Kopf der Säugetiere, besonders der Prosimier, ein Beitrag zum Problem des Formwandels des Säugerschädels. *Z. wiss. Zool.* **157**, 169–219.
- STARCK, D. (1982): Zur Kenntnis der Nase und des Nasenskelettes von *Tarsius* (Mammalia, Primates, Tarsiioidea) *Zool. Garten N.F. Jena* **52**, 289–304.
- WIBLE, J. R.; BHATNAGAR, K. P. (1996): Chiropteran vomeronasal complex and the interfamilial relationship of bats. *J. Mamm. Evol.* **3**, 285–314.
- WÖHRMANN-REPENNING, A. (1978): Geschmacksknospen an der Papilla palatina von *Tupaia glis* (Diard. 1820), ihr Vorkommen und ihre Beziehungen zum Jacobson'schen Organ. *Gegenbaurs morph. Jahrb.* **124**, 375–384.
- WÖHRMANN-REPENNING, A. (1980): The relationship between Jacobson's organ and the oral cavity in a rodent. *Zool. Anz.* **204**, 391–399.
- WÖHRMANN-REPENNING, A. (1981): Die Topographie der Mündungen der Jacobson'schen Organe des Kaninchens (*Oryctolagus cuniculus*) unter funktionellem Aspekt. *Z. Säugetierkunde* **46**, 273–279.
- WÖHRMANN-REPENNING, A. (1982): Vergleichend-anatomische Untersuchungen an Rodentia. Phylogenetische Überlegungen über die Beziehungen der Jacobson'schen Organe zu den Ductus nasopalatini. *Zool. Anz.* **209**, 33–46.
- WÖHRMANN-REPENNING, A. (1984a): Vergleichend anatomische Untersuchungen am Vomeronasalkomplex und am rostralen Gaumen verschiedener Mammalia. *Gegenbaurs morph. Jahrb.* **130**, 501–530; 609–637.
- WÖHRMANN-REPENNING, A. (1984b): Phylogenetische Aspekte zur Topographie der Jacobson'schen Organe und der Ductus nasopalatini bei Insectivora, Primates, *Tupaia* und *Didelphis*. *Anat. Anz.* **157**, 137–149.
- WÖHRMANN-REPENNING, A. (1987): Zur Anatomie des Vomeronasalkomplexes von *Elephantulus rozeti* (Duvernoy, 1830) (Macroscelidea Mammalia). *Zool. Anz.* **218**, 1–8.
- WÖHRMANN-REPENNING, A. (1991): Functional aspects of the vomeronasal complex in mammals. *Zool. Jb. Anat.* **121**, 71–80.
- WÖHRMANN-REPENNING, A. (1993a): The vomeronasal complex – A dual sensory system for olfaction and taste. *Zool. Jb. Anat.* **123**, 337–345.
- WÖHRMANN-REPENNING, A. (1993b): The anatomy of the vomeronasal complex of the fox (*Vulpes vulpes* (L.)) under phylogenetic and functional aspects. *Zool. Jb. Anat.* **123**, 353–361.
- WÖHRMANN-REPENNING, A.; BARTH-MÜLLER, U. (1994): Functional anatomy of the vomeronasal complex in the embryonic development of the pig (*Sus scrofa* dom.) *Acta Theriol.* **39**, 313–323.

Authors' addresses:

Prof. Dr. ANGELA WÖHRMANN-REPENNING, Zoology and Comparative Anatomy, University of Kassel, Heinrich-Plett-Str. 40, D-34132 Kassel, Germany (e-mail: woehrep@hrz.uni-kassel.de)
Dr. MATTHIAS BERGMANN, Nordring 17, D-33330 Gütersloh, Germany.

ZOBODAT - www.zobodat.at

Zoologisch-Botanische Datenbank/Zoological-Botanical Database

Digitale Literatur/Digital Literature

Zeitschrift/Journal: [Mammalian Biology \(früher Zeitschrift für Säugetierkunde\)](#)

Jahr/Year: 2001

Band/Volume: [66](#)

Autor(en)/Author(s): Wöhrmann-Repenning Angela, Bergmann M.

Artikel/Article: [The vomeronasal complex in strepsirhine primates and Tarsius 257-268](#)